Knee Surgery, Sports Traumatology, Arthroscopy
https://doi.org/10.1007/s00167-018-5266-y

KNEE

Recognition of evolving medial patellofemoral anatomy provides insight for reconstruction

Miho J. Tanaka[1] · Jorge A. Chahla[2] · Jack Farr II[3] · Robert F. LaPrade[4] · Elizabeth A. Arendt[5] · Vicente Sanchis-Alfonso[6] · William R. Post[7] · John P. Fulkerson[8,9]

Received: 5 July 2018 / Accepted: 23 October 2018
© European Society of Sports Traumatology, Knee Surgery, Arthroscopy (ESSKA) 2018

Abstract

Purpose The scientific literature concerning the anatomy of medial soft-tissue stabilizers of the patella is growing exponentially. Much of the surgical literature has focused on the role of the medial patellofemoral ligament (MPFL) and techniques to reconstruct it, yet our understanding of its anatomy has evolved during the past several years. Given this, we report on the current understanding of medial patellofemoral anatomy and implications for reconstruction.

Methods Current and historical studies of medial patellar anatomy were reviewed, which include the MPFL and medial quadriceps tendon femoral ligament (MQTFL), as well as that of the distal medial patellar restraints, the medial patellotibial ligament (MPTL) and medial patellomeniscal ligament (MPML). In addition to the reported findings, the authors' anatomic descriptions of each ligament during their dissections were identified and recorded.

Results Despite the name of the MPFL, which implies that the ligament courses between the femur and patella, recent studies have highlighted the proximal MPFL fibers that attach to the quadriceps tendon, known as the MQTFL. The MPFL and MQTFL have also been referred to as the medial patellofemoral complex, reflecting the variability in anatomical attachment sites. The MPFL accounts for only half of the total restraint to lateral patellar displacement, and the remaining contributions to patellar stability are derived from the combination of the MPTL and MPML, which function primarily in greater degrees of knee flexion.

Conclusion The understanding of the complexity of the medial patellar stabilizers continues to evolve. Although MPFL reconstruction is gaining wide acceptance as a procedure to treat patellar instability, it is important to recognize the complex and changing understanding of the anatomy of the medial soft-tissue stabilizers and the implications for reconstruction.

Level of evidence V.

Keywords Anatomy · Knee · Medial patellofemoral ligament · Patellar instability · Reconstruction · Restraints · Soft tissue · Stabilizers

Introduction

The scientific literature concerning the anatomy of medial soft-tissue stabilizers of the patella is growing exponentially. The medial patellofemoral ligament (MPFL) functions as a static restraint to lateral patellar displacement from 0 to 70° of knee flexion [7, 8, 13], and reconstruction of this ligament has been shown to yield consistent improvements in lateral patellar stability [7, 37]. The MPFL was first described in an anatomic cadaveric dissection study by Warren and Marshall [41] as a condensation of fibers extending from the medial epicondyle to the superomedial patella. Conlan et al. [7] expanded on this work with his findings that the MPFL inserts "not only on the patella but also on the undersurface of the distal aspect of the quadriceps mechanism" [p. 682]. However, these proximal fibers have not been highlighted in anatomical discussions or reconstructive techniques until more recently [12, 23, 28, 35]. In light of this, new terms have emerged for the fibers that extend to the quadriceps tendon, including those fibers that course to the tendon, which are labeled the medial quadriceps tendon femoral ligament (MQTFL). A new conceptually helpful term, the medial patellofemoral complex (MPFC), encourages clinicians to recognize the contributions of more than just the traditional

✉ Miho J. Tanaka
Mtanaka4@jhmi.edu

Extended author information available on the last page of the article

Published online: 28 October 2018

role of the MPFL to medial constraint and also recognizes the variability of the individual anatomic structures that occurs in this area.

Despite being considered the primary static stabilizer to the patella, the MPFL accounts for approximately half of the total restraint to lateral patellar displacement [2, 7, 8, 13, 26, 38]. In the original in vitro cutting study by Conlan et al. [7], MPFL contribution to lateral patellar restraint ranged from 23 to 80%. In 7 of 25 knees, the authors reported that the MPFL contributed less than 39% to medial static restraint. Other anatomical and biomechanical studies have shown that the remaining contributions to patellar stability are derived from the medial patellotibial ligament (MPTL) and medial patellomeniscal ligament (MPML), with the combination of these two ligaments reported to contribute 26% to resisting lateral patellar shift in full extension and 46% at 90° of knee flexion [15, 20, 26, 38].

Given the evolving understanding of the medial patellar soft-tissue restraints, a report on the current knowledge of the anatomy and implications for reconstruction in the treatment of patellar instability is needed. In contrast to previous systematic reviews of MPFL anatomy, which have summarized the results of all studies on this topic [1, 27], we highlight the recent literature to update readers on current concepts in patellofemoral anatomy, while revisiting the original anatomical descriptions to provide the context of these changing views. A new framework of terminology for these soft-tissue restraints is discussed, consisting of the proximal medial patellar restraints, which include the MPFL and MQTFL, as well as that of the distal medial patellar restraints, the MPTL and MPML.

Proximal medial patellar restraints

MPFL

Anatomic studies of the MPFL describe this ligament as having a smaller femoral origin and a wide, fan-shaped insertion on the patella and quadriceps tendon [7, 8, 23, 28, 34, 35, 38]. Much attention has focused on the location of the femoral origin and ways to identify proper femoral tunnel placement, given the sensitivity of graft function to the location of its placement on the femur. In anatomic studies, the location of the origin has varied but is most often described as being in the region of the adductor tubercle and medial epicondyle [3, 24, 31, 38], most commonly in the "saddle" between the adductor tubercle and medial epicondyle [5, 21, 22, 26, 28] or within 1 cm distal to the adductor tubercle [11, 31, 39, 42]. It has also been noted to have additional attachments to the medial collateral ligament fibers and/or adductor tendon [3, 8] (Fig. 1). One pediatric study found the femoral origin was 8.5 mm distal to the medial distal

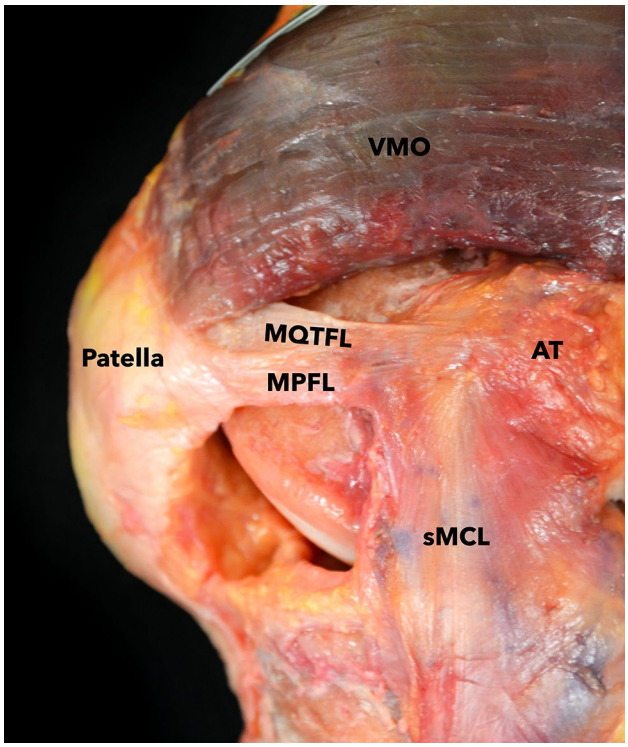

Fig. 1 Medial knee anatomy.Right knee dissection of the medial aspect of the knee showing the spatial relationship between the adductor tubercle (AT) and the medial patellofemoral ligament (MPFL), the medial quadriceps tendon femoral ligament (MQTFL) and the superficial medial collateral ligament (sMCL). VMO, vastus medialis obliquus

femoral physis [9]. The variability in this anatomy has been emphasized, and authors have stressed that the femoral origin should likely be thought of as a "cloud", rather than a "point" [33]. The presence and robustness of these fibers have also been reported to vary. Descriptions of the MPFL fibers and their origin on the femur are detailed in Table 1.

Radiographic landmarks can be used to identify the location of the MPFL femoral origin [4, 16, 20, 44]. However, an exact anatomic femoral attachment point identified by radiographs is not always accurate. Because radiography provides only an approximation of the true anatomy, the femoral attachment point must be determined during surgical exposure on the basis of knowledge of the anatomy to account for person-to-person variability. For example, in women with severe trochlear dysplasia, the radiographic method is less accurate in determining the anatomic femoral fixation point [29]. Schöttle et al. [30] performed eight cadaveric dissections and described the mean point of the femoral origin as 1 mm anterior to the posterior cortical line, 2.5 mm distal to the proximal origin of the medial femoral condyle, and proximal to the posterior aspect of Blumensaat's line. When using intraoperative fluoroscopy to locate this region, some authors have emphasized the importance

Table 1 Femoral origin of the MPFL in anatomic studies

First author (year)	No. of knees (preservation)	Fibers present	Femoral origin	
			Location	Mean size, mm
Desio (1998) [8]	9 (fresh-frozen)	All	Attachments to adductor tubercle, MFE, and MCL	NA
LaPrade (2007) [22]	8 (fresh-frozen)	NA	Attachments to soft tissue between adductor magnus tendon and MCL	11 (range, 8.0–13) proximal and 8.8 (range, 6.7–10) posterior to MFE; 1.9 (range, 1.3–3.2) anterior and 3.8 (range, 2.1–6.3) distal to adductor tubercle
Tuxoe (2002) [38]	39 (unpreserved)	100% (with 5% thin but well-defined)	Adductor tubercle just proximal to insertion of MCL and distal to insertion of adductor magnus tendon; part of superficial MPFL fibers derived from posteromedial capsule in 39 MPFL knees (100%); in 32 knees (82%), part of distal MPFL fibers joined proximal fibers of MCL	NA
Smirk (2003) [31]	25 (embalmed)	All	Posterior part of medial epicondyle, 1 cm distal to adductor tubercle; some with attachment to MCL and adductor tendon	NA
Nomura (2005) [24]	20 (fresh-frozen)	Well-developed (in 7), moderate (in 10), and wispy (in 3)	9.5 ± 1.8 mm proximal and 5.0 ± 1.7 mm posterior to center of MFE	NA
Steensen (2004) [32]	11 (fresh-frozen)	All	Entire length of anterior MFE, with inferior edge of MPFL in contact with superior MCL	15 (range, 11–20)
Panagiotopoulos (2006) [25]	8 (fresh-frozen)	All	MFE in all, except one that originated ~ 10 mm distally directly from MCL	15 ± 3.5
Aragao (2008) [3]	17 (10% formaldehyde solution)	88%	Adductor tubercle (86%); adherent to distal superficial fibers of adductor tendon (67%); related to proximal fibers of MCL (in one)	17 ± 6.0
Baldwin (2009) [5]	50 (fresh or fresh-frozen)	All	Saddle between medial epicondyle and adductor tubercle, with oblique decussation originating from proximal MCL	11 ± 2.9
Philippot (2009) [26]	23 (fresh)	100%; "fleshy" in 15, intermediate in 6, translucent in 2	NA	12 ± 2.6
Kang (2010) [19]	12 (fresh-frozen)	All	8.9 ± 3.3 mm proximally and 13 ± 3.7 mm posteriorly to MFE	NA
Mochizuki (2013) [23]	16 (8% formalin and 30% ethanol)	All	MFE, where MPFL, medial collateral ligament, and adductor magnus tendon appeared to converge at one area	NA

Table 1 (continued)

First author (year)	No. of knees (preservation)	Fibers present	Femoral origin	
			Location	Mean size, mm
Placella (2014) [28]	20 (fresh-frozen)	All	9.5 ± 1.6 mm distal and anterior to adductor tubercle; proximal and posterior to MFE	8.9 ± 3.3
Viste (2014) [39]	12 (embalmed)	All	7.2 ± 2.7 mm proximal and 7.4 ± 4.0 mm posterior to MFE; 11 ± 2.8 mm distal and 1.3 ± 2.1 mm posterior to adductor tubercle; 22 ± 6.4 mm anterior to posterior condyle	8.8 ± 2.9
Tanaka (2016) [34]	32 (embalmed)	4/32 knees had no identifiable MPFL fibers	NA	11 ± 1.8
Tanaka (2016) [35]	25 (NA*)	All	NA	NA
Kruckeberg (2018) [20]	10 (fresh-frozen)	All	14 mm proximal and 2.1 mm posterior to MFE; 8.3 mm distal and 2.7 mm anterior to adductor tubercle	26**

MCL medial collateral ligament, *MFE* medial femoral epicondyle, *MPFL* medial patellofemoral ligament, *MQTFL* medial quadriceps tendon–femoral ligament, *SD* standard deviation, *VI* vastus intermedius, *VMO* vastus medialis obliquus

*Digital images of 25 cadaveric knee dissections

**Expressed as area in mm^2

of using true lateral views to determine the insertion point [4, 44], whereas others have cautioned not to rely solely on radiographic markers because of a limited ability to create an anatomic tunnel [29].

The term "medial patellofemoral ligament", which is used to describe the primary medial soft-tissue restraint of the patella, implies that the fibers extend between the medial patella and the femur. However, because of the understanding that the MPFL has fibers that insert onto both the patella and the quadriceps tendon, some authors [35] have referred to this ligament as the medial patellofemoral complex (MPFC) to express more clearly the burgeoning recognition of the diversity of specific insertion sites. Such findings reflect the complexity of these medial retinacular structures. On close examination of the femoral origins of the MPFC, one finds that structures originating from more distal structures, such as the medial epicondyle, insert more distally, toward the mid-patella. Similarly, MPFC components originating from the more proximal femoral side (e.g., the adductor tubercle itself), course toward and into the quadriceps/vastus intermedius tendon at and proximal to the proximal patella. Although the term "MPFC" was popularized recently, early studies described the presence of proximal MPFL fibers that additionally extend to the quadriceps tendon [7, 31]. Recent studies have re-evaluated the presence and importance of these proximal fibers. The descriptions of the anterior attachments of these fibers, including specific references to the attachments to the quadriceps tendon, are detailed in Table 2.

Medial quadriceps tendon femoral ligament (MQTFL)

Fulkerson and Edgar [12] described the proximal fibers to the quadriceps tendon as a discrete set of fibers, which they termed the MQTFL, and this has been described by others in more recent studies [20]. Other authors, in contrast, have reported these fibers as part of the same condensation of fibers as the MPFL originating from the medial epicondyle [19, 34]. Tanaka [34] reported in a series of 28 cadaveric knees that most ligaments attached to both structures, with 57.3% ± 19.5% of fibers attaching to the patella and the remainder attaching to the quadriceps tendon. Furthermore, the insertion sites were noted to vary, with one knee exhibiting 100% of fibers attaching on the patella and another with a sole attachment to the quadriceps tendon, which may explain the variations in anatomic reports that describe this ligament (Fig. 2). Kang et al. [19] described these fibers as two separate bundles, with the inferior-straight bundle attaching to the patella and the superior oblique fibers attaching to the quadriceps tendon. They reported a mean 25.1° ± 2.1° angle between these two bundles. Given these multiple descriptions, the use of the term MQTFL allows us to distinguish the fibers within this complex that attach specifically to the quadriceps tendon.

Several researchers have discussed functional and surgical considerations related to the wide attachment of this ligament. Fulkerson and Edgar [12] described the reconstruction of the MQTFL, recreating the proximal fibers to the quadriceps tendon. Tanaka et al. [35] identified the midpoint of these fibers as they insert on the patella and vastus intermedius to approximate the potential site of placement for a single-bundle graft. They identified this location as a mean of 2.3% ± 15.8% of the articular length of the patella from the superior pole or at a reproducible point at the junction of the medial border of the quadriceps tendon with the superomedial articular border of the patella (Fig. 3).

Others have considered the length difference between the most proximal and most distal of these fan-shaped fibers with a reported 1.9–7.1 mm length difference between the two, suggesting variable anisometry between these fibers as it relates to changes in anatomic distances between attachment points throughout knee range of motion [19, 34]. Because of this, recent developments in reconstruction techniques have described reconstructing the wide attachment of the fibers [18]. Kang et al. [18] described both Y- and C-shaped grafts that involve fixation first on the femoral side and first on the patellar side, respectively, with minor differences in functional outcomes at 2 years. Wang et al. [40] also reported that although both configurations could restore the stability of the patella, the double-bundle reconstruction had a greater capacity to resist patellar dislocation at 15° of knee flexion but not in greater flexion angles. In both studies, the two fixation points were on the patella. Further studies are needed to understand differences in long-term outcomes of double-bundle techniques, as well as considerations for graft placement on both the patella and quadriceps tendon to anatomically reconstruct the proximal medial patellar restraints.

In addition to its wide proximal–distal insertion, an attachment along the middle of the ligament is adherent directly to the VMO [7, 10, 34, 38]. Conlan [7] described these fibers as fanning out and inserting broadly on the undersurface of the VMO aponeurosis. Descriptions of these findings from previous and recent studies are also noted in Table 1. In dissections by the current authors, the fibers have also been found to decussate with VMO aponeurosis at its midsubstance before inserting onto the vastus intermedius tendon (Fig. 4). Although these anatomic findings may imply an interaction between the MPFC and VMO and could suggest a dynamic role in addition to that of a static stabilizer, further investigations are needed to fully understand the function of these fibers, as well as their implications for reconstruction.

Table 2 Anatomic descriptions of the attachment of the MPFL or MPFC to the patella and/or quadriceps tendon

First author (year)	Patellar attachment location	Mean ± SD anterior attachment size, mm	Description of fibers	
			Attaching to quadriceps tendon	Attaching to VMO
Desio (1998) [8]	Superomedial patella, extending from medial process of patella (inferiorly) to quadriceps tendon (superiorly)	NA	"The patellar attachment of the MPFL was consistently to the superior medial patella, extending from the medial process of the patella inferiorly and to the quadriceps tendon superiorly"	"In each specimen the deep fascia of the VMO attached to the MPFL; however, variability was noted at the level on the medial patellofemoral ligament at which this occurred"
LaPrade (2007) [22]	Broad-based attachment to superomedial patella, with midpoint at 41% of the length from proximal tip of patella	NA	NA	NA
Tuxoe (2002) [38]	Proximal two-thirds of medial margin of patella, as direct insertion and fibers joining quadriceps fibers	NA	NA	"Middle part of the MPFL joins the undersurface of the VMO and the aponeurotic fibers of the vastus intermedius"
Smirk (2003) [31]	Superomedial patella (88%), and undersurface of vastus medialis (100%)	NA	"The ligament was also found to attach to the inferomedial part of the patella (8%), and the quadriceps tendon (48%). In some of these cases (20%), almost the entire ligament extended proximal to the patella"	Attachment to the undersurface of vastus medialis (100%)
Nomura (2005) [24]	Center of patellar attachment was 27% ± 10% from upper end of patella	NA	"Some fibers of the patellar side extended to the more upper aspect than the upper end of the patella"	Attachment to VMO was 20.3 ± 6.1 mm and 35% ± 10% of total length of MPFL
Steensen (2004) [32]	Medial patella	17 (range 14–20)	NA	"In 3 knees, approximately 5% of the width of the MPFL was deep to the VMO"
Panagiotopoulos (2006) [25]	Medial side of patella	25 ± 3.6	NA	"Meshing of the fibers of the VMO to the MPFL close to its patellar insertion"
Aragao (2008) [3]	Medial margin of patella: upper third (13%); middle third (7%); upper and middle thirds (40%); middle and lower thirds (13%); along entire medial length of patella (27%)	28 (range 16–39)	"In one knee, the MPFL was found to be adhered to the deep face of the vastus intermedialis muscle"	80% "partially adhered to the deep face of the VMO"
Baldwin (2009) [5]	Combined attachment with layer 1 and VMO to upper two-thirds of patella	28 ± 5.6	"The upper edge of the transverse ligament that had no bony attachment, was ribbon-like and passed proximal to the patella in all cases, and had a curved attachment to the inferior surface of the vastus medialis obliquus at the musculotendinous junction"	"The body of the anterior MPFL, composed of the transverse and oblique components, became conjoined to the undersurface of the vastus medialis obliquus tendon, and inseparably they attached to the patella"

Table 2 (continued)

First author (year)	Patellar attachment location	Mean ± SD anterior attachment size, mm	Description of fibers	
			Attaching to quadriceps tendon	Attaching to VMO
Philippot (2009) [26]	Upper half of medial patella and patellar end of quadriceps tendon	24 ± 4.8 (range 17–32)	"In all cases, it was also inserted on the patellar end of the quadriceps tendon (although this insertion was much reduced in certain cases)"	"The junction between the VMO and the MPFL was more or less extended but was present in all 23 knees (100%). This appeared as a genuine reflection zone with intertwined MPFL and VMO fibers. The length of this zone where the VMO is inserted on the MPFL measured 25.7 ± 6.0"
Kang (2010) [19]	NA	22 ± 2.9	"The fibers of MPFL fan out to the medial margin of the patella with direct insertion, and the superior bundle of fibers extends out of the upper end of the patella and joins the superior patellar quadriceps fibers"	NA
Mochizuki (2013) [23]	Patella and medial wall of vastus intermedius in all	24 ± 2.1	"MPFL was observed to fan out toward the patella and attached to the medial wall of the vastus intermedius in all specimens"	"MPFL was loosely attached to the distomedial area of the vastus medialis"
Placella (2014) [28]	Proximal third of patella in all; extension to middle third in 11; extension to distal third in 1; extension to quadriceps tendon in 7	25 ± 5.2	"In 7 cases, it extended to the quadriceps tendon"	"In the majority of cases, (14 specimens) MPFL merged with both VMO and VI in the aponeurosis with a surface average of 37.5 mm (SD = 6.4)"
Viste (2014) [39]	Superior half of patella	27 ± 5.9	NA	NA
Tanaka (2016) [34]	57% ± 20% of fibers attaching to patella; remainder to quadriceps tendon	30 ± 5.5	"One knee had all MPFL fibers attaching to the patella, and another had all fibers attaching to the quadriceps tendon. The remainder had attachments to both structures, with 57.3% ± 19.5% (range, 0–100%) of fibers attaching to the patella"	NA
Tanaka (2016) [35]	Patella and vastus intermedius tendon (in 22); vastus intermedius tendon only (in 2); patella only (in 1)	NA	NA	NA
Kruckeberg (2018) [20]	20 mm medial to superior pole on patella	38**	MQTFL had an "insertion length of 29.3 mm on the medial aspect of the distal quadriceps tendon"	NA

**Expressed as area in mm^2

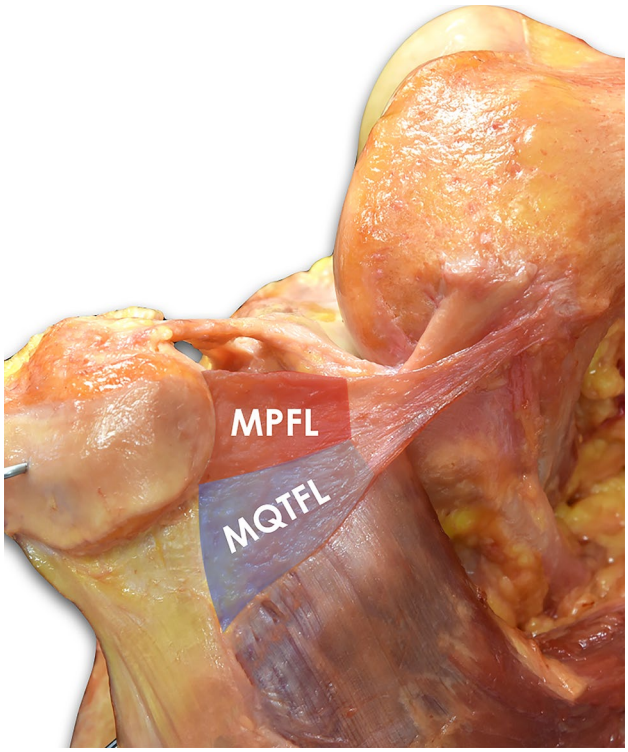

Fig. 2 Articular-sided view of proximal medial patellar restraints. Right knee dissection showing the attachments of the medial patellofemoral ligament (MPFL) on the patella, and the medial quadriceps tendon femoral ligament (MQTFL) on the quadriceps tendon

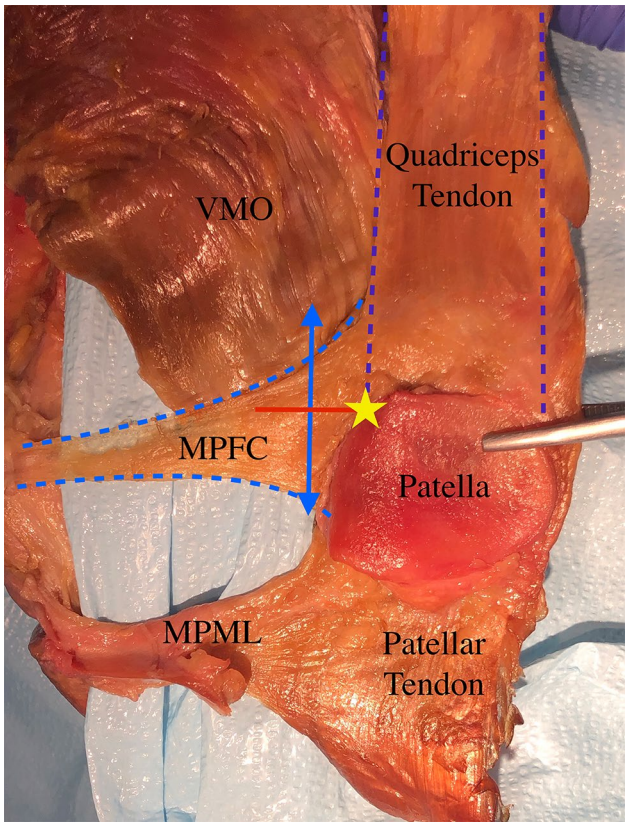

Fig. 3 Midpoint of the medial patellofemoral complex (MPFC). Articular-sided view of the MPFC insertion on the patella and quadriceps tendon, showing a midpoint (star) at the junction of the medial quadriceps tendon border and articular surface of the patella. VMO, vastus medialis obliquus

Distal medial patellar restraints

The distal medial patellar restraints originate on the distal patella and include the MPTL and MPML [14, 15, 17, 20, 21]. Although these are thought of as two separate sets of fibers, a recent study [20] noted that the MPML and MPTL converged to insert on the same location on the inferomedial patella, with the distal portion deep to the patellar tendon and superficial to the capsule. Earlier cadaveric studies also describe the two sets of fibers as a single structure that reinforces the area from the patella to the tibia with extensions to the meniscus [13]. Hinckel et al. [14] reported variability of the origins on the patella, with five of the nine knees having a combined MPML and MPTL on the patella, whereas the MPML was proximal in three and distal in one. They noted that in two cases, the MPML extended also to the tibia, indicating that the MPML and MPTL may have some interrelated functions. Philippot et al. [26] evaluated the medial ligament patella stabilizers from 0°–90° of flexion, reporting that the MPFL was the primary medial stabilizer of the patella in the first 30° of flexion, whereas the MPTL and MPML have an increased role in restriction of lateral translation, patellar tilt, and patellar rotation at 90° of flexion compared with full extension (demonstrating an important role, particularly at higher flexion angles) [26].

MPTL

The MPTL is a thin ligament in layer 2 that serves as a capsular reinforcement and condensation of the medial retinaculum that resists lateral and anterolateral translation of the patella [7, 13, 36]. The fibers originate on the inferomedial patella, 3.6 mm proximal to the distal border of the inferior pole of the patella [7] and insert 14–15 mm distal from the joint line on the anteromedial tibia [14, 36]. Kruckeberg et al. [20] recently identified a bony prominence in this area, termed the medial tibial tubercle, on which the MPTL is reported to insert consistently (Fig. 5.).

The MPTL is 35–50 mm long and 4–22 mm wide [14, 15, 17, 25, 26]. These fibers are more vertically oriented than the

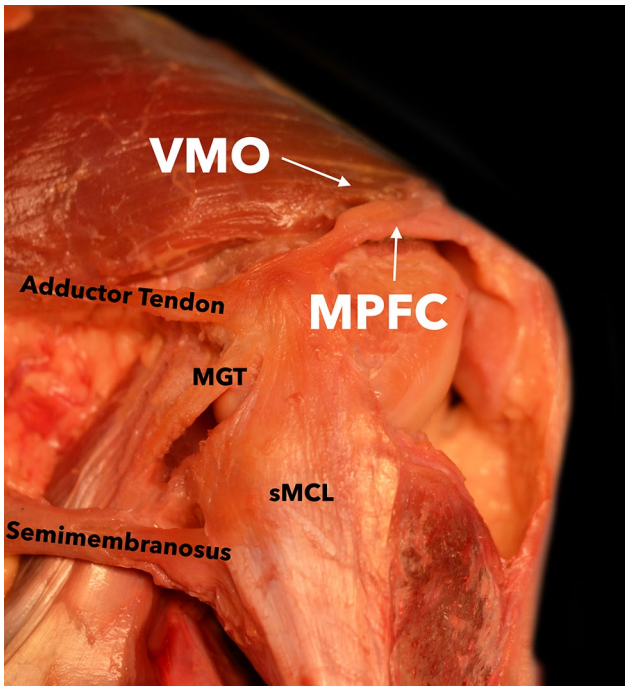

Fig. 4 The medial patellofemoral complex (MPFC) is closely adherent to the vastus medialis obliquus (VMO).Left knee dissection showing MPFC fibers adherent to the undersurface of the VMO. Anatomical landmarks are also depicted, including the medial gastrocnemius (MGT), the superficial medial collateral ligament (sMCL), and the adductor tendon

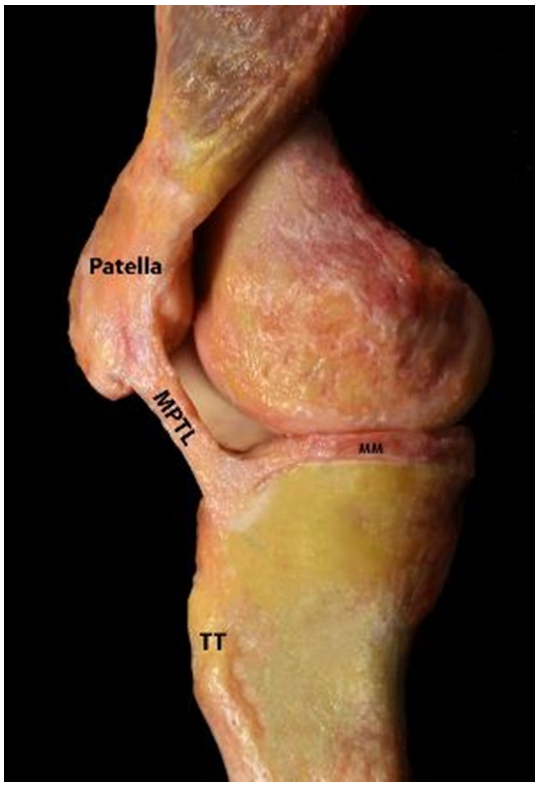

Fig. 5 Medial patellotibial ligament (MPTL) anatomy.Right knee dissection showing the MPTL inserting into the medial tibial tubercle. *MM* medial meniscus, *TT* tibial tubercle

MPFL and course in a more superficial plane [7, 20]. The MPTL courses in a "steep inferomedial orientation" from the inferomedial patella to tibia, at a 20°–25° angle relative to the patellar tendon [7, 17, 25]. A summary of anatomic descriptions of the MPTL is provided in Table 3. Because of this close relationship to the patellar tendon, some authors have described the reconstruction of these fibers as mimicking the medialization of the patellar tendon. One such technique was described by Zaffagnini et al. [43], in which the medial fibers of the patellar tendon are attached to the tibia. The authors reported on outcomes of 29 knees after undergoing MPTL reconstruction with good clinical and radiographic outcomes and a 14% failure rate at a mean follow-up of 6.1 years. Further studies are needed to understand the role and indications for MPTL reconstruction in the setting of patellar instability.

MPML

The MPML is a round, cord-like ligament superficial and adherent to the medial capsule. It is thought to contribute more to patellar stability than the MPTL, with forces accounting for 22% of the total restraint against lateral patellar translation [8, 17]. It can be identified in layer 3, within the deep capsular layer [7, 20]. It is 20–40 mm long and 3–10 mm wide [15, 17, 25, 26]. A summary of anatomical descriptions of the MPML is provided in Table 4. The MPML has a narrow origin of 3–5 mm on the inferomedial patella, at a point described as 5.7 mm proximal to the distal border of the patella [7, 14, 38]. It has a "close relation to the infrapatellar fat pad" [38] (p. 139) and a wide attachment to the anterior horn of the medial meniscus. Hinckel et al. [14] noted that this meniscal attachment was variable. The MPML is thought have more horizontally oriented fibers than the MPTL [20]. It has been described as having an

Table 3 Results of anatomic studies describing the MPTL

First author (year)	No. of knees	Mean ± SD size, mm		MPTL		Orientation with respect to patellar tendon
		Length	Width	Origin	Insertion	
Conlan (1993) [7]	25 (fresh-frozen)	NA		NA	NA	NA
Desio (1998) [8]	9 (fresh-frozen)	NA		Medial border of patella	> 1 cm below joint line	Oblique condensation of fibers from layer 1 that coalesces with fibers of MPFL
Tuxoe (2002) [38]	39 (unpreserved)	NA		NA	NA	NA
Panagiotopoulos (2006) [25]	8 (fresh-frozen)	NA		Lower patellar pole	Medial tibia, 15–20 mm below joint line, 15–20 mm medial to patellar tendon	Range, 20°–25° angle to patellar tendon
Philippot (2009) [26]	23 (fresh) found in 11 knees (47%)	55 ± 8.4	22 ± 4.4	NA	NA	NA
Kaleka (2017) [17]	30 (10% formaldehyde solution)	46 ± 8.8*	NA	Inferomedial patellar border near articular surface; width 12 ± 3.4 mm	18 ± 3.4 mm on anteromedial tibia	22° ± 7.6°
Hinckel (2017) [14]	9 (fresh-frozen)	36 ± 6.4	7.1 ± 2.0	3.4 ± 3.6 mm from lower patellar pole	NA	18.5° ± 4.9°
Kruckeberg (2018) [20]	10 (fresh-frozen)	NA		Mean area, 27 mm^2 (CI 20, 35) combined with MPML center of origin 3.5 mm medial and 3.5 mm proximal to medial border of patellar tendon attachment	Area, 46 mm^2 (CI 35, 58) on tibia	8.3° (CI 5.7, 11)
LaPrade (2018) [21]	22 (fresh-frozen)	NA	4.6 ± 8.8	NA	NA	NA

CI confidence interval, *MPFL* medial patellofemoral ligament, *MPTL* medial patellotibial ligament, *NA* not available, *SD* standard deviation

*Present in 27 knees

Table 4 Results of anatomic studies describing the MPML

First author (year)	No. of knees (preservation)	Mean ± SD size, mm		MPML		Orientation with respect to patellar tendon
		Length	Width	Origin	Attachment	
Conlan (1993) [7]	25 (fresh-frozen)	NA		Lower patellar pole	Anterior horn of MM and meniscotibial coronary ligament	NA
Desio (1998) [8]	9 (fresh-frozen)	NA		Inferior two-thirds of patella	Anterior portion of MM	NA
Tuxoe (2002) [38]	39 (unpreserved)	NA		Narrow insertion (range, 0.3–0.5 cm) at inferomedial corner of patella in layer 3	Wide insertion at anterior horn of MM	NA
Panagiotopoulos (2006) [25]	8 (fresh-frozen)	22 ± 2.2	4.1 ± 0.92	Lower patellar pole	Medial capsulomeniscal region	Range 15°–30° angle
Philippot (2009) [26]	23 (fresh)	39 ± 3.2*	9.6 ± 1.2*	NA	NA	
Kaleka (2017) [17]	30 (10% formaldehyde solution)	37 ± 7.3†	NA	Lower patellar pole, distal to origin of the MPTL; mean width, 8.5 ± 2.6 mm	Mean, 6.7 ± 1.9 mm at anterior horn of MM	Mean, 24° ± 6.6°
Hinckel (2017) [14]	9 (fresh-frozen)	34 ± 3.3	8.3 ± 3.2	Mean, 5.7 ± 5.4 mm from lower patellar pole	NA	Mean, 43° ± 12°
Kruckeberg (2018) [20]	10 (fresh-frozen)	NA		Mean area, 27 mm^2 (CI 20, 35) combined with MPTL	38 mm^2 (32, 45) attachment, 20 mm from center of anterior MM insertion	23° (CI 15, 30)
LaPrade (2018) [21]	22 (fresh-frozen)	53 ± 11	NA	NA	NA	NA

MM medial meniscus, *MPML* medial patellomeniscal ligament, *NA* not available, *SD* standard deviation

*Based on 11 knees

†Based on 29 knees

orientation of 15°–30° relative to the patellar tendon, compared with 20°–25° relative to the MPML [17, 25] (Fig. 6).

Conclusions

The understanding of the complexity of the medial patellar stabilizers continues to evolve. While MPFL reconstruction is gaining wide acceptance as a procedure to treat patellar instability, we emphasize the importance of not only proper patient selection and adding concurrent procedures when necessary [6], but also recognizing the complex and changing understanding of the anatomy of the medial soft-tissue stabilizers that we aim to reconstruct. Further studies to elucidate the clinical and biomechanical roles of these additional medial patellar stabilizers can guide advances in anatomical soft-tissue reconstruction in the treatment of patellofemoral instability.

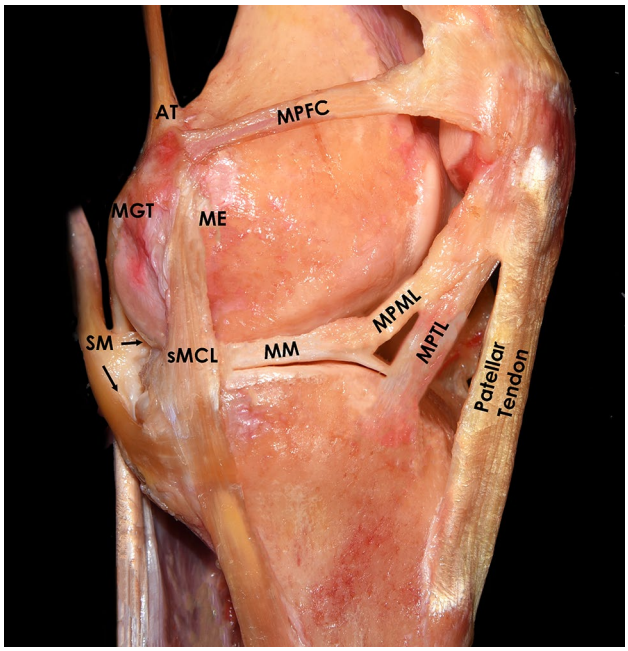

Fig. 6 Proximal and distal medial patellar restraints.Left knee dissection showing medial restraints to lateral patellar translation. The medial patellofemoral complex (MPFC), medial patellotibial ligament (MPTL), and the medial patellomeniscal ligament (MPML), and its anatomical relationship with the adductor tubercle (AT) and the medial epicondyle (ME) are seen. The superficial medial collateral ligament (sMCL), the medial meniscus (MM), semimembranosus (SM), and medial gastrocnemius (MGT) are also depicted

Author contributions MJT participated in study design, drafted the manuscript, and provided figures. JAC contributed to manuscript editing and provided figures. RFL contributed to manuscript editing and provided figures. JF participated in manuscript design, structure, and editing. EAA contributed to manuscript concept and editing. VSA contributed to manuscript concept and editing. WRP contributed to manuscript editing. JPF contributed to manuscript concept and editing. All authors read and approved the final manuscript. MJT, JF, EAA, VSA, JPF, and WP are members of the International Patellofemoral Study Group. WP is the chairman of this group. JPF is the president of the Patellofemoral Foundation.

Funding No funding was received in support of this work.

Compliance with ethical standards

Conflict of interest EAA is a consultant for Smith and Nephew. All other authors declare that they have no competing interests.

Ethical approval There was no research involving human participants as this was a review paper.

Informed consent For this type of study formal consent is not required.

References

1. Aframian A, Smith TO, Tennent TD, Cobb JP, Hing CB (2017) Origin and insertion of the medial patellofemoral ligament: a systematic review of anatomy. Knee Surg Sports Traumatol Arthrosc 25:3755–3772
2. Amis AA, Firer P, Mountney J, Senavongse W, Thomas NP (2003) Anatomy and biomechanics of the medial patellofemoral ligament. Knee 10:215–220
3. Aragao JA, Reis FP, de Vasconcelos DP, Feitosa VLC, Nunes MAP (2008) Metric measurements and attachment levels of the medial patellofemoral ligament: an anatomical study in cadavers. Clinics (Sao Paulo) 63:541–544
4. Balcarek P, Walde TA (2015) Accuracy of femoral tunnel placement in medial patellofemoral ligament reconstruction: the effect of a nearly true-lateral fluoroscopic view. Am J Sports Med 43:2228–2232
5. Baldwin JL (2009) The anatomy of the medial patellofemoral ligament. Am J Sports Med 37:2355–2361
6. Becker R, Hirschmann MT, Karlsson J (2018) The complexity of patellofemoral instability. Knee Surg Sports Traumatol Arthrosc 26:675–676
7. Conlan T, Garth WP Jr, Lemons JE (1993) Evaluation of the medial soft-tissue restraints of the extensor mechanism of the knee. J Bone Jt Surg Am 75:682–693
8. Desio SM, Burks RT, Bachus KN (1998) Soft tissue restraints to lateral patellar translation in the human knee. Am J Sports Med 26:59–65
9. Farrow LD, Alentado VJ, Abdulnabi Z, Gilmore A, Liu RW (2014) The relationship of the medial patellofemoral ligament attachment to the distal femoral physis. Am J Sports Med 42:2214–2218
10. Feller JA, Feagin JA Jr, Garrett WE Jr (1993) The medial patellofemoral ligament revisited: an anatomical study. Knee Surg Sports Traumatol Arthrosc 1:184–186
11. Fujino K, Tajima G, Yan J, Kamei Y, Maruyama M, Takeda S, Kikuchi S, Shimamura T (2015) Morphology of the femoral insertion site of the medial patellofemoral ligament. Knee Surg Sports Traumatol Arthrosc 23:998–1003
12. Fulkerson JP, Edgar C (2013) Medial quadriceps tendon-femoral ligament: surgical anatomy and reconstruction technique to prevent patella instability. Arthrosc Tech 2:e125–e128
13. Hautamaa PV, Fithian DC, Kaufman KR, Daniel DM, Pohlmeyer AM (1998) Medial soft tissue restraints in lateral patellar instability and repair. Clin Orthop Relat Res 349:174–182
14. Hinckel BB, Gobbi RG, Demange MK, Pereira CAM, Pecora JR, Natalino RJM, Miyahira L, Kubota BS, Camanho GL (2017) Medial patellofemoral ligament, medial patellotibial ligament, and medial patellomeniscal ligament: Anatomic, histologic, radiographic, and biomechanical study. Arthroscopy 33:1862–1873
15. Hinckel BB, Gobbi RG, Kaleka CC, Camanho GL, Arendt EA (2018) Medial patellotibial ligament and medial patellomeniscal ligament: anatomy, imaging, biomechanics, and clinical review. Knee Surg Sports Traumatol Arthrosc 26:685–696
16. Jaecker V, Brozat B, Banerjee M, Otchwemah R, Bouillon B, Shafizadeh S (2017) Fluoroscopic control allows for precise tunnel positioning in MPFL reconstruction. Knee Surg Sports Traumatol Arthrosc 25:2688–2694
17. Kaleka CC, Aihara LJ, Rodrigues A, de Medeiros SF, de Oliveira VM, de Paula Leite Cury R (2017) Cadaveric study of the secondary medial patellar restraints: patellotibial and patellomeniscal ligaments. Knee Surg Sports Traumatol Arthrosc 25:144–151
18. Kang H, Cao J, Yu D, Zheng Z, Wang F (2013) Comparison of 2 different techniques for anatomic reconstruction of the medial

patellofemoral ligament: a prospective randomized study. Am J Sports Med 41:1013–1021
19. Kang HJ, Wang F, Chen BC, Su YL, Zhang ZC, Yan CB (2010) Functional bundles of the medial patellofemoral ligament. Knee Surg Sports Traumatol Arthrosc 18:1511–1516
20. Kruckeberg BM, Chahla J, Moatshe G, Cinque ME, Muckenhirn KJ, Godin JA, Ridley TJ, Brady AW, Arendt EA, LaPrade RF (2018) Quantitative and qualitative analysis of the medial patellar ligaments: an anatomic and radiographic study. Am J Sports Med 46:153–162
21. LaPrade MD, Kallenbach SL, Aman ZS, Moatshe G, Storaci HW, Turnbull TL, Arendt EA, Chahla J, LaPrade RF (2018) Biomechanical evaluation of the medial stabilizers of the patella. Am J Sports Med 46:1575–1582
22. LaPrade RF, Engebretsen AH, Ly TV, Johansen S, Wentorf FA, Engebretsen L (2007) The anatomy of the medial part of the knee. J Bone Joint Surg Am 89:2000–2010
23. Mochizuki T, Nimura A, Tateishi T, Yamaguchi K, Muneta T, Akita K (2013) Anatomic study of the attachment of the medial patellofemoral ligament and its characteristic relationships to the vastus intermedius. Knee Surg Sports Traumatol Arthrosc 21:305–310
24. Nomura E, Inoue M, Osada N (2005) Anatomical analysis of the medial patellofemoral ligament of the knee, especially the femoral attachment. Knee Surg Sports Traumatol Arthrosc 13:510–515
25. Panagiotopoulos E, Strzelczyk P, Herrmann M, Scuderi G (2006) Cadaveric study on static medial patellar stabilizers: the dynamizing role of the vastus medialis obliquus on medial patellofemoral ligament. Knee Surg Sports Traumatol Arthrosc 14:7–12
26. Philippot R, Chouteau J, Wegrzyn J, Testa R, Fessy MH, Moyen B (2009) Medial patellofemoral ligament anatomy: implications for its surgical reconstruction. Knee Surg Sports Traumatol Arthrosc 17:475–479
27. Placella G, Tei M, Sebastiani E, Speziali A, Antinolfi P, Delcogliano M, Georgoulis A, Cerulli G (2015) Anatomy of the medial patello-femoral ligament: a systematic review of the last 20 years literature. Musculoskelet Surg 99:93–103
28. Placella G, Tei MM, Sebastiani E, Criscenti G, Speziali A, Mazzola C, Georgoulis A, Cerulli G (2014) Shape and size of the medial patellofemoral ligament for the best surgical reconstruction: a human cadaveric study. Knee Surg Sports Traumatol Arthrosc 22:2327–2333
29. Sanchis-Alfonso V, Ramirez-Fuentes C, Montesinos-Berry E, Elia I, Marti-Bonmati L (2017) Radiographic location does not ensure a precise anatomic location of the femoral fixation site in medial patellofemoral ligament reconstruction. Orthop J Sports Med 5:2325967117739252
30. Schottle PB, Schmeling A, Rosenstiel N, Weiler A (2007) Radiographic landmarks for femoral tunnel placement in medial patellofemoral ligament reconstruction. Am J Sports Med 35:801–804
31. Smirk C, Morris H (2003) The anatomy and reconstruction of the medial patellofemoral ligament. Knee 10:221–227
32. Steensen RN, Dopirak RM, McDonald WG III (2004) The anatomy and isometry of the medial patellofemoral ligament: implications for reconstruction. Am J Sports Med 32:1509–1513
33. Stephen JM, Lumpaopong P, Deehan DJ, Kader D, Amis AA (2012) The medial patellofemoral ligament: location of femoral attachment and length change patterns resulting from anatomic and nonanatomic attachments. Am J Sports Med 40:1871–1879
34. Tanaka MJ (2016) Variability in the patellar attachment of the medial patellofemoral ligament. Arthroscopy 32:1667–1670
35. Tanaka MJ, Voss A, Fulkerson JP (2016) The anatomic midpoint of the attachment of the medial patellofemoral complex. J Bone Jt Surg Am 98:1199–1205
36. Terry GC (1989) The anatomy of the extensor mechanism. Clin Sports Med 8:163–177
37. Testa EA, Camathias C, Amsler F, Henle P, Friederich NF, Hirschmann MT (2017) Surgical treatment of patellofemoral instability using trochleoplasty or MPFL reconstruction: a systematic review. Knee Surg Sports Traumatol Arthrosc 25:2309–2320
38. Tuxoe JI, Teir M, Winge S, Nielsen PL (2002) The medial patellofemoral ligament: a dissection study. Knee Surg Sports Traumatol Arthrosc 10:138–140
39. Viste A, Chatelet F, Desmarchelier R, Fessy MH (2014) Anatomical study of the medial patello-femoral ligament: landmarks for its surgical reconstruction. Surg Radiol Anat 36:733–739
40. Wang Q, Huang W, Cai D, Huang H (2017) Biomechanical comparison of single- and double-bundle medial patellofemoral ligament reconstruction. J Orthop Surg Res 12:29
41. Warren LF, Marshall JL (1979) The supporting structures and layers on the medial side of the knee: an anatomical analysis. J Bone Jt Surg Am 61:56–62
42. Wijdicks CA, Griffith CJ, LaPrade RF, Johansen S, Sunderland A, Arendt EA, Engebretsen L (2009) Radiographic identification of the primary medial knee structures. J Bone Jt Surg Am 91:521–529
43. Zaffagnini S, Grassi A, Marcheggiani Muccioli GM, Luetzow WF, Vaccari V, Benzi A, Marcacci M (2014) Medial patellotibial ligament (MPTL) reconstruction for patellar instability. Knee Surg Sports Traumatol Arthrosc 22:2491–2498
44. Ziegler CG, Fulkerson JP, Edgar C (2016) Radiographic reference points are inaccurate with and without a true lateral radiograph: The importance of anatomy in medial patellofemoral ligament reconstruction. Am J Sports Med 44:133–142

Affiliations

Miho J. Tanaka[1] · Jorge A. Chahla[2] · Jack Farr II[3] · Robert F. LaPrade[4] · Elizabeth A. Arendt[5] · Vicente Sanchis-Alfonso[6] · William R. Post[7] · John P. Fulkerson[8,9]

Jorge A. Chahla
jachahla@msn.com

Jack Farr II
jfarr@orthoindy.com

Robert F. LaPrade
rlaprade@thesteadmanclinic.com

Elizabeth A. Arendt
arend001@umn.edu

Vicente Sanchis-Alfonso
vicente.sanchis.alfonso@gmail.com

William R. Post
wpost@wvortho.com

John P. Fulkerson
patelladoc@aol.com

[1] Department of Orthopaedic Surgery, Johns Hopkins University School of Medicine, 601 N. Caroline St., Suite 5250, 21287 Baltimore, MD, USA

[2] Cedars-Sinai Kerlan Jobe Institute, Santa Monica, CA, USA

[3] OrthoIndy Knee Preservation and Cartilage Restoration Center, Orthopedic Surgery, Indiana University School of Medicine, Indianapolis, IN, USA

[4] The Steadman Clinic, Vail, CO, USA

[5] Department of Orthopaedic Surgery, University of Minnesota, Minneapolis, MN, USA

[6] Department of Orthopaedic Surgery, Hospital Arnau de Vilanova, Valencia, Spain

[7] Mountaineer Orthopedic Specialists, LLC, Morgantown, WV, USA

[8] Orthopedic Associates of Hartford, Farmington, CT, USA

[9] Department of Orthopedic Surgery, University of Connecticut School of Medicine, Farmington, CT, USA