

Anatomical and Functional Results After Arthroscopic Hill-Sachs Remplissage

Pascal Boileau, MD, Kieran O'Shea, MD, Pablo Vargas, MD, Miguel Pinedo, MD, Jason Old, FRCSC, and Matthias Zumstein, MD

Investigation performed at the Department of Orthopaedic Surgery and Sports Traumatology, L'Archet Hospital II, University of Nice-Sophia-Antipolis, Nice, France

Background: Large osseous defects of the posterosuperior aspect of the humeral head can engage the glenoid rim and cause recurrent instability after arthroscopic Bankart repair for glenohumeral dislocation. Filling of the humeral head defect with the posterior aspect of the capsule and the infraspinatus tendon (i.e., Hill-Sachs remplissage) has recently been proposed as an additional arthroscopic procedure. Our hypothesis is that the capsulotenodesis heals in the humeral bone defect without a severe adverse effect on shoulder mobility, allowing return to preinjury sports activity.

Methods: Of 459 patients operated on for recurrent traumatic anterior shoulder instability, forty-seven (10.2%) underwent arthroscopic Bankart repair combined with Hill-Sachs remplissage with use of suture anchors. All had a large Hill-Sachs lesion (Calandra grade III), engaging over the glenoid rim, without substantial glenoid bone loss. Nine patients had had prior unsuccessful surgery to address glenohumeral instability (three Bankart and six Bristow-Latarjet procedures). The average age at the time of surgery (and standard deviation) was 29 ± 5.4 years. Postoperatively, comparative shoulder motion was precisely measured with use of digital photographic images. Capsulotenodesis healing was assessed on a computed tomography (CT) arthrogram ($n = 38$) or magnetic resonance image (MRI) ($n = 4$). The mean duration of follow-up was twenty-four months.

Results: Healing of the posterior aspect of the capsule and the infraspinatus tendon into the humeral defect was observed in all forty-two patients who underwent postoperative imaging, and thirty-one (74%) had a remplissage of $\geq 75\%$. Compared with the normal (contralateral) side, the mean deficit in external rotation was $8^\circ \pm 7^\circ$ with the arm at the side of the trunk and $9^\circ \pm 7^\circ$ in abduction at the time of the last follow-up. Of forty-one patients involved in sports, thirty-seven (90%) were able to return postoperatively and twenty-eight (68%) returned to the same level of sports, including those involving overhead activities. Ninety-eight percent (forty-six) of the forty-seven patients had a stable shoulder at the time of the last follow-up.

Conclusions: Arthroscopic Hill-Sachs remplissage, performed in combination with a Bankart repair, is a potential solution for patients with a large engaging humeral head bone defect but no substantial glenoid bone loss. The posterior capsulotenodesis heals predictably in the humeral defect. The slight restriction in external rotation (approximately 10°) does not significantly affect return to sports, including those involving overhead activities. The procedure, which may also be useful for revision of previous failed glenohumeral instability surgery, is not indicated for patients with glenoid bone deficiency.

Level of Evidence: Therapeutic Level IV. See Instructions for Authors for a complete description of levels of evidence.

Posterosuperior humeral head bone defects, commonly known as Hill-Sachs lesions, have been reported to occur in 47% of individuals with a first-time glenohumeral dislocation and in up to 90% of those with recurrent antero-inferior glenohumeral instability¹⁻⁵. With recurrent episodes of glenohumeral instability, the lesions become larger and deeper,

increasing the risk of further instability⁶⁻¹⁰. The term “engaging Hill-Sachs lesion” has been used by Burkhart and De Beer to describe a compression fracture of the humeral head that is large enough for the edge of the humeral head to drop over the glenoid rim as the arm is abducted and externally rotated¹¹. Such large and engaging defects of the posterosuperior aspect

Disclosure: None of the authors received payments or services, either directly or indirectly (i.e., via his or her institution), from a third party in support of any aspect of this work. One or more of the authors, or his or her institution, has had a financial relationship, in the thirty-six months prior to submission of this work, with an entity in the biomedical arena that could be perceived to influence or have the potential to influence what is written in this work. No author has had any other relationships, or has engaged in any other activities, that could be perceived to influence or have the potential to influence what is written in this work. The complete **Disclosures of Potential Conflicts of Interest** submitted by authors are always provided with the online version of the article.

of the humeral head are associated with a higher rate of recurrent glenohumeral instability after arthroscopic Bankart repair^{6,11}. In previous studies, patients with a large humeral head bone defect were at risk for failure of isolated arthroscopic labral repair and were poor candidates for that procedure^{6,12}.

Filling of the humeral head defect with the posterior aspect of the capsule and the infraspinatus tendon is a surgical procedure proposed in 1972 by Connolly to decrease the likelihood of postoperative redislocation¹³. By filling the abraded humeral defect, the lesion is rendered extra-articular, preventing the humeral head from engaging the glenoid rim. In addition, the posterior capsulotenodesis acts as a checkrein diminishing anterior humeral head translation and reducing the risk of postoperative redislocation. In 2004, Wolf et al. described, as a modification of Connolly's open surgical method, the arthroscopic technique of Hill-Sachs "remplissage" (French for "filling") performed in combination with Bankart repair^{14,15}.

In 2005, we started to perform this combined arthroscopic procedure for patients with a large and engaging Hill-Sachs lesion without substantial glenoid bone loss. The present prospective trial, in which both clinical and imaging studies were used for evaluation, was designed to determine the safety and efficacy of this novel arthroscopic combined procedure in a cohort of patients with a large and engaging posterosuperior

humeral defect but no substantial glenoid deficiency. We hypothesized that the capsulotenodesis heals into the humeral head defect without producing any severe adverse effect on postoperative shoulder motion, thereby allowing a return to preinjury levels of sports activity, and that this healing improves the shoulder stability achieved following stabilization surgery.

Materials and Methods

Patient Selection

Our operative indications for patients who present with symptomatic recurrent traumatic anteroinferior instability of the shoulder were redefined in 2005, on the basis of previous clinical experience (Fig. 1). We first screened the patients with use of the ISIS (Instability Severity Index Score)^{6,12}. This 10-point scale uses clinical and imaging parameters to determine the risk of treatment failure following isolated arthroscopic Bankart repair. Patients with an ISIS of <3 points were offered an arthroscopic Bankart repair. Patients with a score of ≥3 points are at an unacceptably high (>10%) risk of recurrent instability following isolated arthroscopic Bankart repair. All patients underwent, in addition to routine preoperative radiography, multiplanar computed tomography (CT) scans, which were carefully evaluated for evidence of substantial glenoid lesions^{6,11}. In addition, the glenoid was arthroscopically assessed by viewing from both the posterior and the anterosuperior portal, as described by Burkhart et al., for evidence of an inverted pear glenoid^{6,8,11,16}. Substantial glenoid bone loss, detected on imaging or at arthroscopy, was a contraindication to isolated Bankart repair and/or Bankart repair combined with Hill-Sachs remplissage, and patients with such loss were treated with a Bristow-Latarjet procedure instead¹⁷. The arthroscopic Bankart-

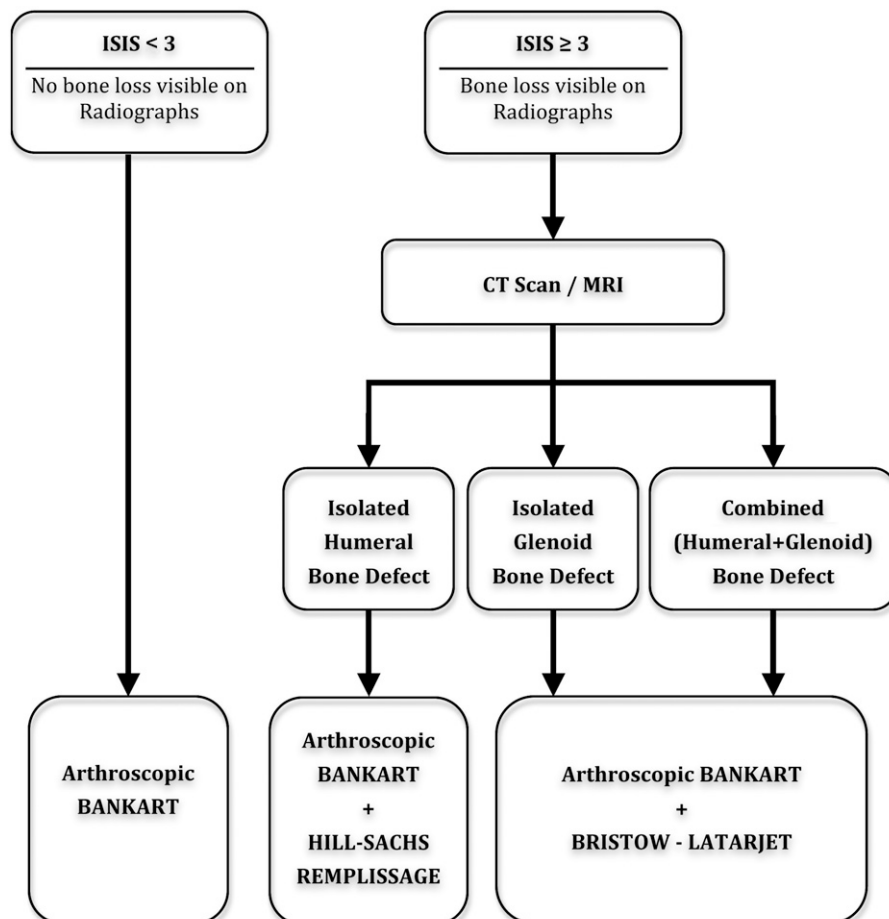


Fig. 1
Indications for surgical treatment of chronic anterior shoulder instability since 2005 in our orthopaedic department. ISIS = Instability Severity Index Score¹².

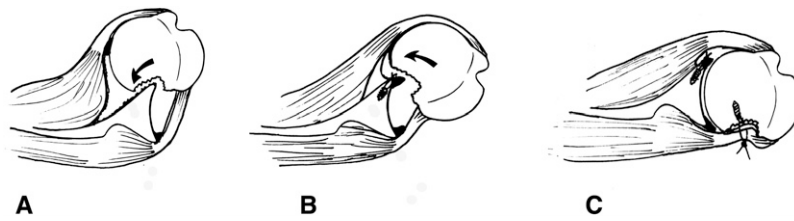


Fig. 2

Biomechanics of Hill-Sachs lesions and Hill-Sachs remplissage. **Fig. 2-A** Impactation of the posterior aspect of the humeral head on the anterior glenoid rim produces the engaging Hill-Sachs lesion. **Fig. 2-B** Recurrence of anterior instability despite anterior Bankart repair because of engagement of the large Hill-Sachs lesion on the anterior glenoid rim. **Fig. 2-C** The transfer (and healing) of the capsule and infraspinatus tendon into the bone defect has the dual effects of (1) placing the humeral osseous lesion extra-articularly (exclusion effect), and (2) decreasing anterior translation (checkrein effect).

Hill-Sachs remplissage procedure was offered as treatment only to patients with a large (Calandra grade-III)¹ and engaging Hill-Sachs lesion without substantial glenoid bone loss.

Thus, patients were considered suitable for inclusion in the present study if they had (1) an ISIS of >3 points; (2) no substantial glenoid bone deficiency detected on radiographs, CT or magnetic resonance imaging (MRI) scanning, or arthroscopy; (3) an isolated, large (Calandra¹ grade-III) Hill-Sachs lesion engaging over the glenoid rim at any degree of abduction/external rotation during diagnostic arthroscopy; and (4) a clinical examination performed at least one year after surgery by independent observers with comparative digitalized measurement of shoulder motion. Patients with failed previous stabilization (a failed Bankart or Bristow-Latarjet procedure) were considered to be suitable for inclusion if they had no substantial glenoid bone loss on imaging studies or during arthroscopic examination and if the humeral bone defect was thought to be the cause of failure.

We excluded from this investigation patients with any of the following:

- (1) symptomatic recurrent anterior glenohumeral instability associated with only soft-tissue lesions, (2) substantial glenoid bone loss, (3) first-time anterior glenohumeral dislocation, (4) voluntary posterior or multidirectional instability, (5) anterior instability associated with a full-thickness rotator cuff tear, and (6) severe preexisting glenohumeral osteoarthritis.

The risks and benefits of the arthroscopic procedure were explained to all patients, who gave written informed consent prior to enrollment. The local institutional review board approved the study.

Surgical Technique

The combined arthroscopic procedure was performed with the patient in the beach-chair position and under general anesthesia with an interscalene nerve

block. In addition to the standard posterior and anterosuperior portals, an accessory posterolateral portal centered over the Hill-Sachs lesion (the “remplissage portal”) was required so that suture anchors could be inserted orthogonal to the surface of the humeral bone defect^{14,15,18}. The goals of the Bankart-Hill-Sachs remplissage procedure are (1) to fill the posterosuperior humeral defect with the capsule and the infraspinatus tendon with use of suture anchors, and (2) to reinsert the anterior aspect of the labrum and capsule with suture anchors (Fig. 2). From a strategic perspective, it is important to perform the four steps in the following order to minimize operative delay and difficulty (Fig. 3).

Step 1: Glenoid Preparation and Passage of Traction Sutures Through the Anterior Aspect of the Labrum and Capsule

With the arthroscope in the posterior portal, the labrum and the inferior glenohumeral ligament were mobilized so that they could be shifted superiorly and laterally. After placement of one or two temporary outside traction sutures¹⁹, the anterior glenoid rim was debrided from 2 to 6 o'clock with a shaver (Smith & Nephew, Andover, Massachusetts); a burr was not used to prevent iatrogenic glenoid bone loss.

Step 2: Hill-Sachs Preparation and Humeral Anchor Insertion

With the humeral head anteriorly translated, a spinal needle localized the posterolateral portal (two fingerbreadths lateral to the posterior portal). Rotation of the humeral head was controlled so that the needle arrived strictly perpendicular and central to the bone defect. The humeral defect was abraded with a shaver. Two single-loaded anchors (Quick-T [Smith & Nephew] or Spiralok [DePuy Mitek, Raynham, Massachusetts]), one superior and one inferior and both adjacent to the margin of the defect, were placed.

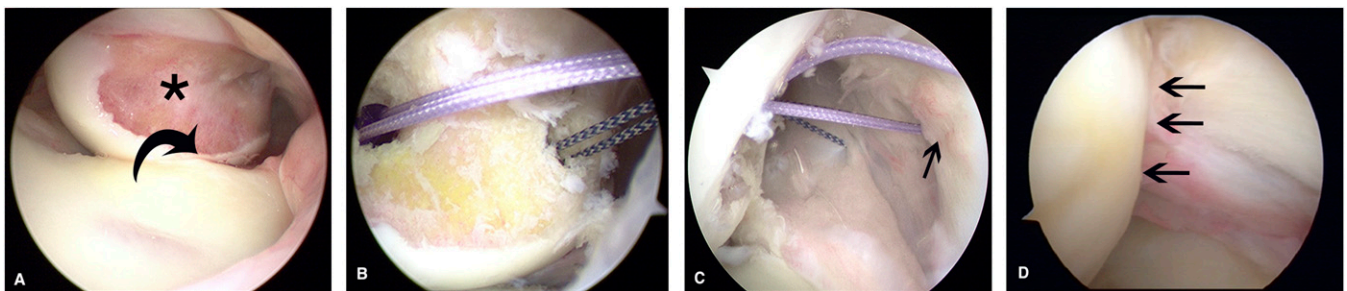


Fig. 3

Arthroscopic views showing Hill-Sachs remplissage. **Fig. 3-A** At arthroscopy, the Hill-Sachs lesion (asterisk) is engaging over the anterior glenoid rim (curved arrow) when the arm is brought in abduction and external rotation, but there is no glenoid bone loss. **Fig. 3-B** Two suture anchors (of different colors) are introduced into the base of the humeral defect, one superior and one inferior and both adjacent to the margin of the defect (intra-articular view from posterior). **Fig. 3-C** The two anchors with the four limbs of sutures are ready to be tied over the infraspinatus tendon (arrow). **Fig. 3-D** Once the sutures have been tied, the Hill-Sachs lesion is filled with the posterior aspect of the capsule and the infraspinatus tendon (arrows).

TABLE I Postoperative Comparative Active Shoulder Mobility at Six Months and at the Time of the Last Follow-up*

	AAE (°)	ER1 (°)	ER2 (°)	IR1 (points)	IR2 (°)
6 mo postop.					
Operatively treated shoulder†	170 ± 13	49 ± 15	69 ± 17	8.7 ± 1.3	66 ± 14
Contralateral shoulder†	178 ± 4	63 ± 12	85 ± 13	9.9 ± 0.5	72 ± 14
Difference†	8 ± 13	14 ± 14	16 ± 12	1.2 ± 1.3	6 ± 9
P value	<0.001	<0.001	<0.001	<0.001	<0.001
Last follow-up (mean, 24 mo)					
Operatively treated shoulder†	175 ± 7	55 ± 16	76 ± 12	9.3 ± 1.1	64 ± 11
Contralateral shoulder†	177 ± 5	63 ± 16	85 ± 13	9.8 ± 0.6	69 ± 11
Difference†	2 ± 4	8 ± 7	9 ± 7	0.5 ± 0.9	5 ± 6
P value	0.002	<0.001	<0.001	0.003	<0.001

*AAE = active anterior elevation, ER1 = external rotation with the arm at the side, ER2 = external rotation in abduction, IR1 = internal rotation of the hand to the back, and IR2 = internal rotation in abduction. †The values are given as the mean and standard deviation.

Step 3: Suture Passing and Filling of the Humeral Defect

The arthroscope was then transferred to the anterosuperior portal while the cannula inserted in the posterolateral portal was withdrawn into the subdeltoid space. With use of a penetrating grasper (CleverHook [DePuy Mitek]), one limb of each suture was retrieved through the posterior aspect of the capsule and the infraspinatus tendon. With the humeral head reduced and the arm placed in neutral rotation, two mattress stitches were tied on the rotator cuff's bursal side, creating the capsulotenodesis (Fig. 3).

Step 4: Capsulolabral (i.e., Bankart) Repair

The arthroscope was then switched back through the posterior portal. A classic arthroscopic Bankart repair was performed with suture anchors (Lupine [DePuy Mitek]), with use of a previously described technique⁶.

Postoperative Care

No modifications to our rehabilitation program following Bankart repair were made for patients treated with the remplissage in association with the Bankart repair⁶. The arm was placed in a sling in neutral rotation for four weeks. Self-directed rehabilitation with pendulum exercises was started on the day after surgery (five times a day, five minutes each session, as a rule). Formal, physiotherapist-supervised rehabilitation commenced at four weeks following surgery. The patients were permitted to return to sports activity between three and six months postoperatively.

Clinical Assessment

The patients were prospectively evaluated at three, six, and twelve months and yearly thereafter by three independent observers (K.O'S., M.P., and P.V.). The mean duration of follow-up was twenty-four months (range, twelve to forty-three months). Postoperative shoulder function was assessed with use of the Rowe, Walch-Duplay, and Constant-Murley scores^{3,6,19-21}. Patients were asked to assign a percentage value to their shoulder in comparison with that of a normal shoulder (subjective shoulder value, or SSV)²². Digital photographic images were made to document the range of shoulder motion in active forward elevation, internal and external rotation in adduction, and internal and external rotation in abduction. These images were imported into the OsiriX Imaging Software²³, enabling precise measurement of shoulder mobility.

Postoperative Assessment of Posterior Capsulotenodesis Healing

CT arthrograms of the operatively treated shoulder were obtained at least six months after surgery. The CT images, in DICOM (Digital Imaging and Com-

munications in Medicine) format, were also manipulated with use of the OsiriX Imaging Software²³. Precise reconstructions in the coronal, parasagittal, and axial planes were performed. The absence of intra-articular contrast medium in the base of the humeral head defect was indicative of 100% filling, or remplissage. Four orthopaedic surgeons independently analyzed the images. The percentage of filling (i.e., percentage of remplissage) was classified with use of four grades: complete (100%), 75% to 99%, 50% to 74%, and <50%. Interobserver agreement was high (Cronbach alpha, 0.928).

Statistical Analysis

Measurements were expressed as the mean and range. The D'Agostino-Pearson test was used to analyze data distribution. Paired values were compared by using the paired t test, and unpaired results were compared by using the Mann-Whitney test. The chi-squared test was used to compare categorical data. The significance level was set at $p < 0.05$.

Source of Funding

No funding was received for this study.

Results

Patient Population

Between September 2005 and April 2009, 459 patients underwent surgery for the treatment of traumatic, recurrent anterior glenohumeral instability. Forty-seven (10.2%) of these patients who met the inclusion criteria underwent arthroscopic Hill-Sachs remplissage in combination with a Bankart repair. There were forty-two male patients and five female patients. The average age at the time of surgery (and standard deviation) was 29 ± 5.4 years (range, fourteen to fifty-eight years). The dominant arm was involved in 64% (thirty) of the forty-seven cases. The mean ISIS was 3.8 (range, 3 to 6)¹². All patients had a history of frank episodes of glenohumeral dislocation requiring reduction under sedation or anesthesia in an emergency department on at least one occasion. The mean number of dislocations per patient was four (range, two to twenty). Twenty-two (47%) of the forty-seven patients also experienced subjective episodes of recurrent glenohumeral subluxation. The mean interval between the onset of glenohumeral instability and surgery was seventy-seven months (range, nine to 334 months). Nine

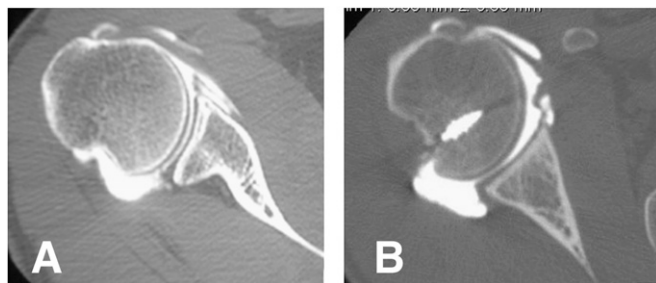


Fig. 4

Evidence of capsule and tendon healing in the humeral bone defect.

Fig. 4-A Preoperative CT arthrogram showing the deep posterior bone defect. **Fig. 4-B** Postoperative CT arthrogram, made ten months after surgery, demonstrating healing of the soft tissues and complete (100%) filling of the Hill-Sachs defect.

patients (19%) had a failed previous stabilization (six failed open Bristow-Latarjet procedures, one failed open Bankart procedure, and two failed arthroscopic Bankart repairs). Preoperative CT scans and intraoperative evaluation revealed humeral-side bone loss, a recurrent labral lesion, and preservation of glenoid bone stock in all nine patients. Of the six patients with a prior open Bristow-Latarjet procedure, three had healing of the coracoid bone block to the glenoid and the other three had a fibrous union.

Anatomical Results (Capsulotenodesis Healing)

Forty-two patients (89%) agreed to undergo postoperative imaging at least six months after surgery to assess capsulotenodesis healing. Thirty-eight patients had CT arthrography, and four patients, unwilling to undergo arthrography, had MRI scans instead. Both imaging studies can be used to evaluate healing of capsule and tendon to bone^{24,25}. There was evidence of healing of the posterior aspect of the capsule and the infraspinatus tendon into the humeral defect in all forty-two patients (Fig. 4). Of the forty-two patients with postoperative imaging studies, thirty-one (74%) had remplissage of >75%. Only two patients had filling of <50% (Fig. 5).

Functional Results

One patient had a traumatic glenohumeral redislocation at twenty-five months postoperatively, sustained during a fall while playing basketball with another player landing on the abducted upper extremity. No other patient had objective evidence of additional dislocations or subluxations or anterior apprehension on clinical examination at the time of the last follow-up.

The mean Rowe score (and standard deviation) was 91 ± 11 points (range, 60 to 100 points), the mean Walch-Duplay score was 89.5 ± 12 points (range, 50 to 100 points), and the mean Constant-Murley score was 94 ± 7 points (range, 70 to 100 points). According to the criteria established by the Walch-Duplay score²¹, 87% (forty-one) of the forty-seven patients had good-to-excellent results.

Postoperative Comparative Shoulder Mobility

Postoperative comparative shoulder mobility at six months and at the time of the last follow-up is summarized in Table I.

Compared with the normal (contralateral) side, the mean deficit in external rotation was $8^\circ \pm 7^\circ$ with the arm at the side and $9^\circ \pm 7^\circ$ in abduction at the time of the last follow-up (see Appendix). No patient expressed dissatisfaction with the slight reduction in external rotation. Only one patient reported some discomfort when the arm was maximally externally rotated in 90° abduction.

Return to Sports Activity

Of the forty-one patients actively participating in sports activities prior to the onset of symptoms of glenohumeral instability, five were at a competitive professional level. The primary type of sport in which the patient participated, as categorized in the Walch-Duplay score, was risk-free in eight cases, with contact in twenty-one, with cocking of the arm in nine, and high risk in three. Postoperatively, thirty-seven patients (90%) returned to sports activity (Table II). Twenty-eight patients (68%) returned at the same level as prior to the onset of the instability, six returned to a lower level, and three changed to a different sports activity postoperatively. Of the five patients competing at a professional level preoperatively, four were able to return to sports activity at the same level postoperatively. All four patients who had not returned to sports at the time of the last review stated that it was for reasons independent of the shoulder.

Subjective Results

The sole patient who was disappointed with the result of the procedure was the one with a postoperative anterior glenohumeral dislocation; all others were very satisfied or satisfied. The mean SSV²² increased from 58% (range, 20% to 90%) preoperatively to 90% (range, 70% to 100%) postoperatively.

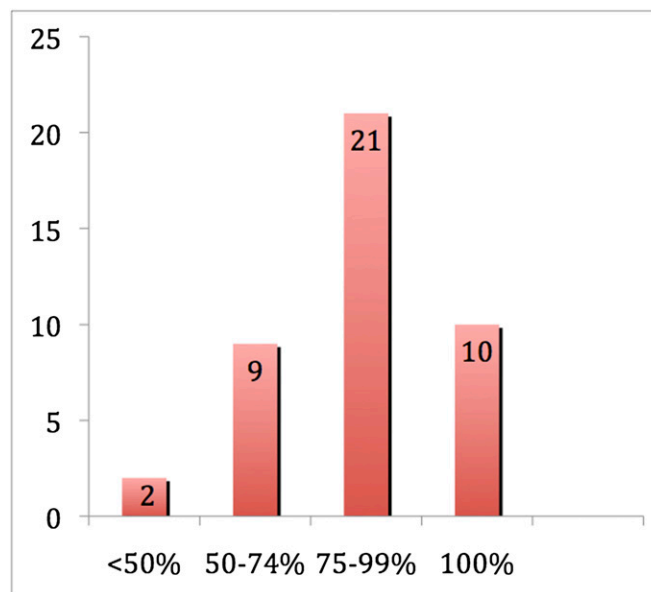


Fig. 5

Percentage of remplissage, or filling, of the Hill-Sachs defect as evaluated on postoperative imaging studies (thirty-eight CT arthrograms and four MRIs), performed at least six months after surgery.

TABLE II Preoperative and Postoperative Sports Activities

	No risk	Contact	Arm Overhead	High Risk	Total
Preop.	8	21	9	3	41
Postop.	8	20	7	2	37

Complications and Reoperations

No shoulder sustained iatrogenic nerve injury, and there were no wound infections. The patient who had a recurrence of instability was eighteen years old at the time of surgery, played basketball at a competitive level, and had evidence of hyperlaxity on preoperative clinical examination (an ISIS of 5 points). Postoperative CT arthrography revealed a remplissage of 75% to 99%. This episode was isolated and, at the time of the latest follow-up, the patient continued to compete fully in contact and overhead sports.

Only one patient underwent repeat surgery; this was for symptomatic persistent tenosynovitis of the long head of the biceps tendon, which occurred one year after the index surgery. The symptoms resolved after the arthroscopic biceps tenodesis. Healing of the posterior capsulotenodesis with complete remplissage of the humeral bone defect was noted during the surgery, in keeping with the postoperative findings on CT arthrography.

Discussion

The purpose of the present study was to evaluate the anatomical and functional results after arthroscopic Hill-Sachs “remplissage” combined with Bankart repair in patients presenting with recurrent anterior glenohumeral instability associated with an isolated engaging humeral head bone defect. No patient had substantial glenoid bone loss in this series. The results of the study confirm our three hypotheses: (1) the posterior capsulotenodesis heals predictably into the humeral head defect, (2) this healing does not produce any severe adverse effect on postoperative shoulder range of motion (the slight restriction—approximately 10°—in external rotation observed did not prevent 90% of the patients from returning to their preinjury sports activities), and (3) at the time of the last follow-up, 98% of the patients had a stable shoulder. In addition, the combined procedure was useful for revision of previous failed glenohumeral instability surgery when humeral head bone loss was identified as the main cause of recurrence.

Our first goal was to verify that the capsulotenodesis effectively heals into the humeral head bone defect. On imaging studies, all patients showed some evidence of healing of the posterior aspect of the capsule and the infraspinatus in the humeral defect, and the soft tissues filled >75% of the humeral defect in the majority of cases (Figs. 4 and 5). The results suggest that capsulotenodesis healing is a prerequisite for a successful outcome, but the minimum amount of remplissage needed to confer stability is not yet known. The fact that the two patients with healing of <50% reported excellent subjective and objective results is inconclusive. Our interpretation is that both procedures (Bankart repair and Hill-Sachs remplissage) probably contribute to postoperative shoulder stability. This

result reinforces our belief that Hill-Sachs remplissage should never be performed in isolation but always in combination with a standard arthroscopic Bankart repair.

Since this is a nonanatomical technique, our second goal was to clarify if healing of the soft tissues in the humeral bone defect would have an adverse effect on postoperative shoulder motion and return to sports activity²⁶⁻²⁸. The magnitude of restriction of shoulder motion after the procedure in our study was relatively small: an average of 8° in external rotation with the arm at the side and 9° in external rotation with the arm in abduction. Due to the potential shortening of the arc of motion of the humeral head related to the remplissage, one could have expected a greater limitation of shoulder mobility²⁹. In fact, values reported for restriction of external rotation following arthroscopic Bankart repair alone are not different from those we are reporting following the combined labral repair and remplissage procedure⁸. It may be that the labral repair and anterior capsular retensioning are the most important factors contributing to postoperative restriction of external rotation²⁹. Our findings support Connolly's postulation that the procedure affords maximum stability by affecting mainly humeral translation and not rotation¹³. The fact that 90% of our patients were able to return to sports activity, including overhead activities, suggests that there is probably a functional adaptation of the shoulder after surgery with a “rebalancing” between scapulothoracic and glenohumeral motion (see Appendix).

Our third goal was to evaluate whether healing of the soft tissues in the humeral bone defect would improve shoulder stability in patients with a humeral head bone defect. At the time of the last follow-up, only one traumatic glenohumeral redislocation had occurred in our population (a 2% rate). These results confirm the benefit of the additional arthroscopic procedure: by avoiding engagement of the humeral head bone defect on the glenoid rim, the Hill-Sachs remplissage protects the Bankart repair (Fig. 2). Although the recurrence rate may increase with time, these results are better than the previously published outcomes of arthroscopic stabilization with use of suture anchors in patients with humeral head bone loss^{6,7,11,28}. Our results are slightly better than those found by Wolf et al., who reported an 8% rate of recurrent instability after the combined procedure and cited instability with glenoid-side bone loss as a possible indication for arthroscopic Hill-Sachs remplissage^{14,15}. We disagree with this indication, which may lead surgeons to overuse arthroscopic Hill-Sachs remplissage. Our excellent objective results are in part related to our strict operative indications and reinforce our opinion that Hill-Sachs remplissage must be strictly reserved for patients with *isolated* humeral head bone loss (Fig. 6). The forty-seven patients treated in our study accounted for 10%

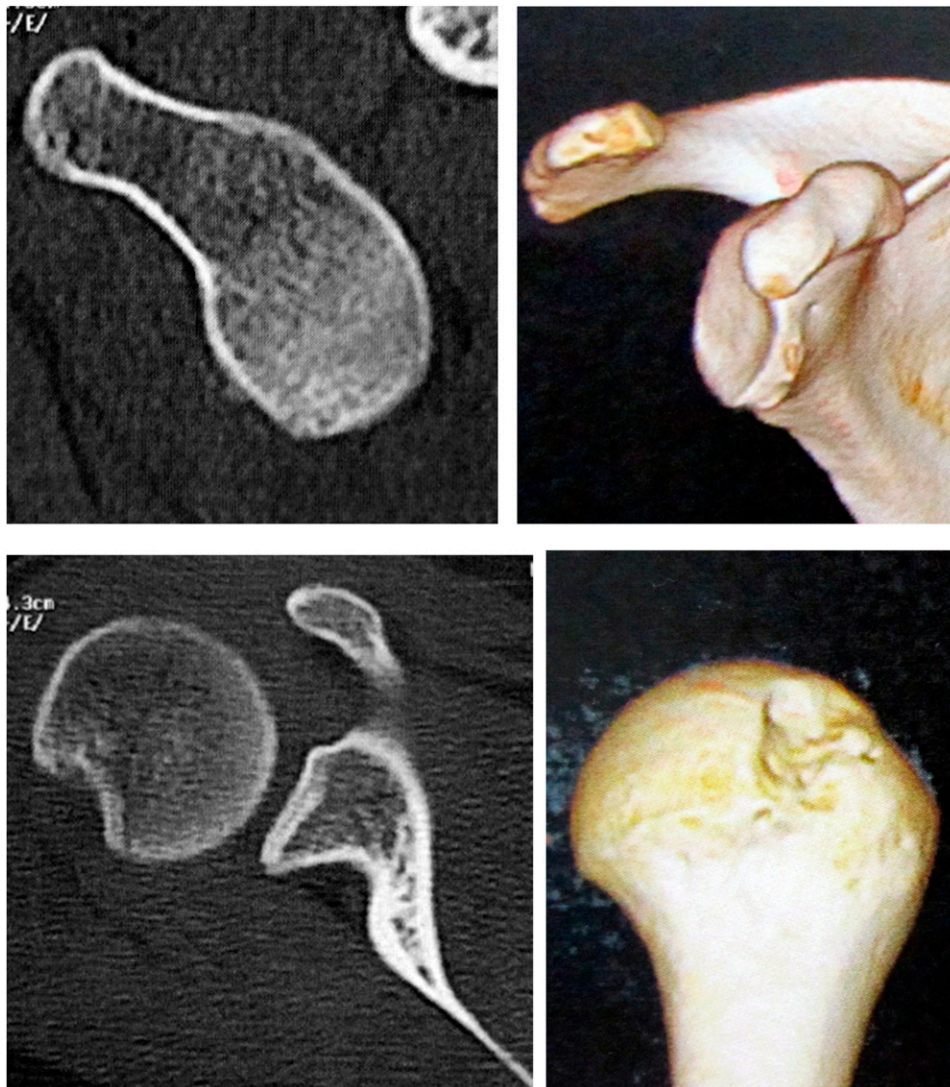


Fig. 6

Three-dimensional CT scan demonstrating the right indication for the Hill-Sachs remplissage procedure: absence of substantial glenoid bone loss (top) and large, deep humeral bone loss (bottom).

of the procedures performed for glenohumeral instability during the study period. In cases of glenoid bone deficiency (in isolation or in association with a humeral defect), the anterior glenoid rim must be reconstructed. In such cases, our preference is to perform a coracoid transfer (i.e., a Bristow-Latarjet procedure)^{6,17,30}.

The management of large engaging humeral-side bone defects in patients with anterior glenohumeral instability is unclear and remains controversial^{31,32}. There are many surgical treatment options to restore or reconstruct humeral head anatomy, including humeroplasty or disimpaction, autograft or allograft reconstruction, rotational humeral osteotomy, partial or complete resurfacing, and hemiarthroplasty^{28,31-42}. It is obvious that, compared with these surgical techniques, arthroscopic Hill-Sachs remplissage is much less invasive: no complications related to the technique were observed in our series. In addition to being less aggressive, the arthroscopic procedure does not “burn any bridges” as it leaves

open the possibility of performing an open procedure if glenohumeral instability persists. Finally, our results show that arthroscopic Bankart-Hill-Sachs remplissage may be used as a salvage procedure in cases of failed prior stabilization. The results of arthroscopic revision surgery are good and predictable when humeral-side bone loss is identified as the etiological factor responsible for recurrence.


Our study is the first to objectively demonstrate that healing of the posterior aspect of the capsule and the infraspinatus in the humeral defect predictably occurs after arthroscopic Hill-Sachs remplissage and the slight limitation in external rotation does not prevent patients from returning to sports, including overhead sports, at the predislocation level. The strengths of our study include a homogeneous patient population with excellent follow-up, patient examination by observers independent of the senior author, and accurate methodology to assess healing and

mobility^{21,23-25}. Although every effort was made to be as precise as possible in the measurement of shoulder motion, we did not measure isolated glenohumeral motion; instead we measured global shoulder motion, incorporating both glenohumeral and scapulohumeral motion. However, this does not weaken our study since it is the difference in postoperative mobility between the two sides that is of clinical relevance.

In conclusion, encouraging clinical and anatomical results have been observed after arthroscopic Hill-Sachs remplissage combined with Bankart repair. The posterior capsulodesis and the infraspinatus tenodesis heal reliably in the humeral head defect and, in the short term, the procedure is effective in stabilizing the shoulder. The slight restriction in external rotation observed is not markedly different from that after an isolated Bankart procedure and did not affect return to sports activity. This all-arthroscopic procedure is indicated in a difficult subgroup of patients with *isolated* humeral head bone loss, for which Bankart repair alone is associated with an unacceptable high rate of recurrent glenohumeral instability. Hill-Sachs remplissage is not indicated for patients with glenoid bone loss. The procedure may be useful in the revision setting following failed instability surgery when humeral head bone loss is identified as the main cause of recurrence. Additional investigations are necessary to

assess the long-term results of this novel arthroscopic procedure and to clarify its indications as well as its biomechanical effects.

Appendix

 Figures showing an example of comparative active mobility in a patient with complete Hill-Sachs remplissage and Bankart repair performed on the left shoulder are available with the online version of this article as a data supplement at jbjs.org. ■

Note: The authors thank Daniel G. Schwartz, MD, for his help in editing the final manuscript.

Pascal Boileau, MD
Kieran O'Shea, MD
Pablo Vargas, MD
Miguel Pinedo, MD
Jason Old, FRCSC
Matthias Zumstein, MD
Department of Orthopaedic Surgery and Sports Traumatology,
Hôpital de L'Archet-University of Nice Sophia-Antipolis, 151,
Route de St Antoine de Ginestière, 06202 Nice, France.
E-mail address for P. Boileau: boileau.p@chu-nice.fr

References

- Calandra JJ, Baker CL, Uribe J. The incidence of Hill-Sachs lesions in initial anterior shoulder dislocations. *Arthroscopy*. 1989;5:254-7.
- Hill HA, Sachs MD. The grooved defect of the humeral head. A frequently unrecognized complication of dislocations of the shoulder joint. *Radiology*. 1940;35:690-700.
- Rowe CR, Patel D, Southmayd WW. The Bankart procedure: a long-term end-result study. *J Bone Joint Surg Am*. 1978;60:1-16.
- Saito H, Itoi E, Minagawa H, Yamamoto N, Tuoheti Y, Seki N. Location of the Hill-Sachs lesion in shoulders with recurrent anterior dislocation. *Arch Orthop Trauma Surg*. 2009;129:1327-34.
- Spatschil A, Landsiedl F, Anderl W, Imhoff A, Seiler H, Vassilev I, Klein W, Boszotta H, Hoffmann F, Rupp S. Posttraumatic anterior-inferior instability of the shoulder: arthroscopic findings and clinical correlations. *Arch Orthop Trauma Surg*. 2006;126:217-22.
- Boileau P, Villalba M, Héry JY, Balg F, Ahrens P, Neyton L. Risk factors for recurrence of shoulder instability after arthroscopic Bankart repair. *J Bone Joint Surg Am*. 2006;88:1755-63.
- Cetik O, Uslu M, Ozsar BK. The relationship between Hill-Sachs lesion and recurrent anterior shoulder dislocation. *Acta Orthop Belg*. 2007;73:175-8.
- Burkhart SS, Danaceau SM. Articular arc length mismatch as a cause of failed bankart repair. *Arthroscopy*. 2000;16:740-4.
- Kralinger FS, Golser K, Wischatta R, Wambacher M, Spemer G. Predicting recurrence after primary anterior shoulder dislocation. *Am J Sports Med*. 2002;30:116-20.
- Voos JE, Livermore RW, Feeley BT, Altchek DW, Williams RJ, Warren RF, Cordasco FA, Allen AA; HSS Sports Medicine Service. Prospective evaluation of arthroscopic bankart repairs for anterior instability. *Am J Sports Med*. 2010;38:302-7.
- Burkhart SS, De Beer JF. Traumatic glenohumeral bone defects and their relationship to failure of arthroscopic Bankart repairs: significance of the inverted pear glenoid and the humeral engaging Hill-Sachs lesion. *Arthroscopy*. 2000;16:677-94.
- Balg F, Boileau P. The instability severity index score. A simple pre-operative score to select patients for arthroscopic or open shoulder stabilisation. *J Bone Joint Surg Br*. 2007;89:1470-7.
- Connolly J. Humeral head defects associated with shoulder dislocations. In: *American Academy of Orthopaedic Surgeons. Instructional course lectures*. St. Louis: Mosby; 1972. p 42-54.
- Wolf EM, Pollack ME. Hill-Sachs "remplissage": an arthroscopic solution for the engaging Hill-Sachs lesion. *Arthroscopy*. 2004;20(Suppl 1):e14-e15.
- Purchase RJ, Wolf EM, Hobgood ER, Pollock ME, Smalley CC. Hill-Sachs "remplissage": an arthroscopic solution for the engaging Hill-Sachs lesion. *Arthroscopy*. 2008;24:723-6.
- Itoi E, Lee SB, Berglund LJ, Berge LL, An KN. The effect of a glenoid defect on anteroposterior stability of the shoulder after Bankart repair: a cadaveric study. *J Bone Joint Surg Am*. 2000;82:35-46.
- Walch G, Boileau P. Latarjet-Bristow procedure for recurrent anterior instability. *Tech Shoulder Elbow Surg*. 2000;1:256-61.
- Toro F, Melean P, Moraga C, Ruiz F, Gonzalez F, Vaisman A. Remplissage: infraspinatus tenodesis and posterior capsulodesis for the treatment of Hill-Sachs lesions: an all intra-articular technique. *Tech Shoulder Elbow Surg*. 2008;9:188-92.
- Boileau P, Ahrens P. The TOTS (temporary outside traction suture): a new technique to allow easy suture placement and improve capsular shift in arthroscopic bankart repair. *Arthroscopy*. 2003;19:672-7.
- Constant CR. Age related recovery of shoulder function after injury [Thesis]. Cork, Ireland: University College; 1986.
- Walch G. [Recurrent shoulder dislocation]. *Rev Chir Orthop Reparatrice Appar Mot*. 1991;77:178-92. French.
- Gilbert MK, Gerber C. Comparison of the subjective shoulder value and the Constant score. *J Shoulder Elbow Surg*. 2007;16:717-21.
- Rosset A, Spadola L, Ratib O. OsiriX: an open-source software for navigating in multidimensional DICOM images. *J Digit Imaging*. 2004;17:205-16.
- Goutallier D, Postel JM, Bernageau J, Lavau L, Voisin MC. Fatty muscle degeneration in cuff ruptures. Pre- and postoperative evaluation by CT scan. *Clin Orthop Relat Res*. 1994;304:78-83.
- Zanetti M, Hodler J. MR imaging of the shoulder after surgery. *Magn Reson Imaging Clin N Am*. 2004;12:169-83, viii.
- Yamamoto N, Itoi E, Abe H, Minagawa H, Seki N, Shimada Y, Okada K. Contact between the glenoid and the humeral head in abduction, external rotation, and horizontal extension: a new concept of glenoid track. *J Shoulder Elbow Surg*. 2007;16:649-56.
- Kaer SG, Fening SD, Jones MH, Colbrunn RW, Miniaci A. Effect of humeral head defect size on glenohumeral stability: a cadaveric study of simulated Hill-Sachs defects. *Am J Sports Med*. 2010;38:594-9.
- Rahme H, Vikersjö O, Ludvigsson L, Elvén M, Michaëlisson K. Loss of external rotation after open Bankart repair: an important prognostic factor for patient satisfaction. *Knee Surg Sports Traumatol Arthrosc*. 2010;18:404-8.
- Barlow B, Peace W, Metzger P, Leonardelli D, Solomon DJ. Clinical grading of Hill-Sachs injuries: association with glenoid bone loss and clinical application of the "glenoid track" concept—when is there humeral head engagement? Presented at the AOSSM 2010 Annual Meeting; 2010 Jul 15-18; Providence, RI.
- Boileau P, Mercier N, Roussanne Y, Thélu CÉ, Old J. Arthroscopic Bankart-Bristow-Latarjet procedure: the development and early results of a safe and reproducible technique. *Arthroscopy*. 2010;26:1434-50.

- 31.** Armitage MS, Faber KJ, Drosdowech DS, Litchfield RB, Athwal GS. Humeral head bone defects: remplissage, allograft, and arthroplasty. *Orthop Clin North Am.* 2010;41:417-25.
- 32.** Lynch JR, Clinton JM, Dewing CB, Warne WJ, Matsen FA 3rd. Treatment of osseous defects associated with anterior shoulder instability. *J Shoulder Elbow Surg.* 2009;18:317-28.
- 33.** Gerber C, Lambert SM. Allograft reconstruction of segmental defects of the humeral head for the treatment of chronic locked posterior dislocation of the shoulder. *J Bone Joint Surg Am.* 1996;78:376-82.
- 34.** Grondin P, Leith J. Case series: Combined large Hill-Sachs and bony Bankart lesions treated by Latarjet and partial humeral head resurfacing: a report of 2 cases. *Can J Surg.* 2009;52:249-54.
- 35.** Kazel MD, Sekiya JK, Greene JA, Bruker CT. Percutaneous correction (humero-plasty) of humeral head defects (Hill-Sachs) associated with anterior shoulder instability: a cadaveric study. *Arthroscopy.* 2005;21:1473-8.
- 36.** Kropf EJ, Sekiya JK. Osteoarticular allograft transplantation for large humeral head defects in glenohumeral instability. *Arthroscopy.* 2007;23:322.e1-5.
- 37.** Miniaci A, Berlet G. Recurrent anterior instability following failed surgical repair: allograft reconstruction of large humeral head defects. *J Bone Joint Surg Br.* 2001;83:19-20.
- 38.** Re P, Gallo RA, Richmond JC. Transhumeral head plasty for large Hill-Sachs lesions. *Arthroscopy.* 2006;22:798.e1-4.
- 39.** Bushnell BDB, Creighton RA, Herring MM. Hybrid treatment of engaging Hill-Sachs lesions: arthroscopic capsulolabral repair and limited posterior approach for bone-grafting. *Techn Shoulder Elbow Surg.* 2007;8:194-203.
- 40.** Sekiya JK, Wickwire AC, Stehle JH, Debski RE. Hill-Sachs defects and repair using osteoarticular allograft transplantation: biomechanical analysis using a joint compression model. *Am J Sports Med.* 2009;37:2459-66.
- 41.** Kronberg M, Broström LA. Rotation osteotomy of the proximal humerus to stabilise the shoulder. Five years' experience. *J Bone Joint Surg Br.* 1995; 77:924-7.
- 42.** Weber BG, Simpson LA, Hardegger F. Rotational humeral osteotomy for recurrent anterior dislocation of the shoulder associated with a large Hill-Sachs lesion. *J Bone Joint Surg Am.* 1984;66:1443-50.