



Suprapectoral biceps tenodesis with bicortical drilling procedures: anatomic analysis of chondral and axillary nerve risk with transhumeral pin guide

Miguel Pinedo, MD^{a,b}, Cristobal Calvo, MD^{b,*}, Max Ekdahl, MD^a,
Vicente Gutierrez, MD^a

^a*Clinica Las Condes, Santiago, Chile*

^b*School of Medicine, Universidad de los Andes, Santiago, Chile*

Background: Many biceps tenodesis (BT) procedures are described for treating proximal biceps pathology. Axillary nerve injury has been reported during BT using bicortical drilling techniques with variable results depending on the location. In addition, there is a risk of potential articular damage during suprapectoral BT. We sought to determine the distance between the axillary nerve and the posterior passage of a bicortical pin, as well as the risk of articular damage, and to analyze whether a lateral inclination of the pin could avoid the chondral risk during suprapectoral BT with bicortical drilling.

Methods: Ten cadaveric shoulders were divided into 2 groups. In the first group, we determined the axillary nerve distance from the posterior exit point of 3 pins in a suprapectoral position 15 mm distal to the humeral cartilage: perpendicular, 10° caudal, and 20° caudal inclination. We measured 2 distances from the pin: to the axillary nerve and to the cartilage border. In the second group, we set one pin at the same perpendicular position and set the second pin 15° laterally tilted to determine its extra-articular passage.

Results: No pin injured the nerve, whereas all pins showed a transchondral direction. The 20° caudal inclination was the nearest to the nerve (18.8 mm [95% confidence interval, 5.5–32 mm]), but the perpendicular position was the safer position (38.8 mm [95% confidence interval, 28–49.6 mm]). Tilting the pin direction 15° laterally prevented cartilage damage ($P = .008$).

Conclusions: Suprapectoral BT with bicortical drilling performed 15 mm distal to the humeral cartilage is a safe procedure regarding the axillary nerve. A potential humeral chondral injury could be prevented with 15° of lateral inclination of the pin guide.

Level of evidence: Anatomy Study; Cadaveric Dissection

© 2019 Journal of Shoulder and Elbow Surgery Board of Trustees. All rights reserved.

Keywords: Long head of biceps; suprapectoral tenodesis; bicortical drilling; axillary nerve; chondral damage; interference screw

Biceps tenodesis (BT) is a valid procedure for treating long head of the biceps pathology.^{2,5,6,10,17,19} It can be

performed in a subpectoral or suprapectoral location. Suprapectoral BT is performed in the bicipital groove; it can be performed in the upper, middle, or lower portion of the groove. Many techniques have been described in each position, including suture anchors, cortical buttons, and interference screws.^{1,3,9,13} In 2002, Boileau et al³ published a suprapectoral arthroscopic BT technique with an

Our institutional review board approved this study (Comité Ético Científico, Universidad de los Andes; no. CEC201846).

*Reprint requests: Cristobal Calvo, MD, Martin Alonso Pinzon 5250, Dep 2004, Las Condes, 7590292, Santiago, RM, Chile.

E-mail address: cpcalvo@gmail.com (C. Calvo).

interference screw using bicortical drilling with a trans-humeral Beath pin toward the posterior humeral cortex to pull the biceps into the bone tunnel.

As the axillary nerve crosses around the posterior aspect of the humeral neck, it can be at risk during procedures with posterior cortex perforation. Although a neurologic injury is a rare complication, some authors described this injury in open subpectoral BT.^{12,14} Cadaveric studies showed the axillary nerve risk during bicortical BT procedures but focused mainly on the subpectoral location, with a few authors analyzing suprapectoral BT with variable results.^{1,4,8,15,16}

Articular cartilage perforation is another potential risk of the guide pin passage through the posterior cortex that has not been previously described. Theoretically, when the guide pin is placed perpendicular to the bicipital groove at its upper portion, it could perforate the humeral head. Our group accidentally adverted this situation in late post-operative shoulder magnetic resonance imaging in some patients. To our knowledge, there are no studies regarding chondral injury with this technique.

The first purpose of this study was to determine the distance between the axillary nerve and the posterior exit of a traction guide pin placed in an anterior-to-posterior direction at the bicipital groove, as well as to establish the risk of articular cartilage perforation with this technique. The second purpose was to analyze whether

adding lateral tilting to the pin could prevent the chondral violation.

Materials and methods

Ten paired fresh-frozen cadaveric upper limbs (5 right and 5 left) were used. The specimens were thawed 2 days before dissection and measurements. We performed a standard delto-pectoral approach, identifying the bicipital groove and long head of the biceps, which was tenotomized for clear vision of the bicipital groove at its upper border to the articular cartilage. According to the technique of Boileau et al,³ a 15-mm distance from the upper border was measured. The suprapectoral location was defined to preserve appropriate tenodesis tension, considering the intra-articular portion of the long head of the biceps to measure 35 mm^{7,11} and a tendon stump to measure 25 mm (50 mm plicated). At this point, we divided the specimens into 2 groups according to our 2 purposes: In the first group (3 right and 2 left shoulders), we measured the axillary nerve distance and the distance from the pin to the chondral border; in the second group (2 right and 3 left shoulders), we sought to determine whether lateral angulation of the pin could prevent the chondral perforation risk. We decided to divide the cadavers into 2 groups to prevent errors produced by repetitive drilling through the bone.

In the first group, in the previously mentioned position, three 2.0-mm needles were placed at different caudal angulations: 0° (perpendicular to the groove cortex), 10° caudal, and 20°

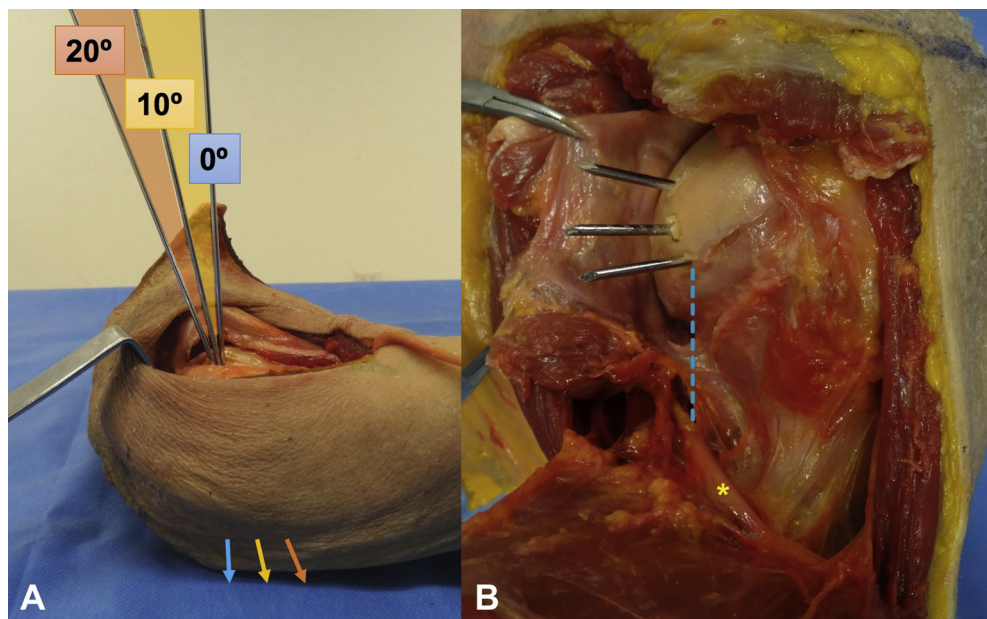


Figure 1 Pins positioning in specimens. (A) Three pins were situated at the bicipital groove 15 mm distal from the upper border in the following positions: perpendicular, 10° caudal, and 20° caudal. We previously set the humerus, with the forearm attached, in approximately 30° of internal rotation. Then, we placed the pins immediately adjacent to each other in the horizontal plane at the same distance (15 mm) from the upper portion of the groove because, otherwise, there would be a path conflict between them. The arrows show the intentional posteroinferior direction to be closer to the axillary nerve. (B) The posterior approach was made carefully; then, the smaller distances were measured: pin to axillary nerve (*, blue line) and pin to cartilage border (if the pin was transchondral).

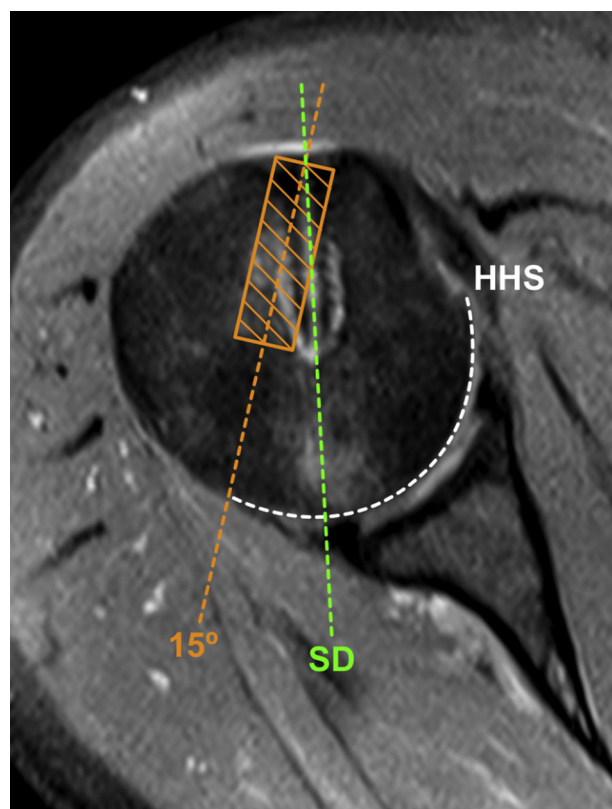


Figure 2 Standard and lateralized pin directions: schema of the transchondral pin direction on a postoperative magnetic resonance image after suprapectoral biceps tenodesis according to the described technique.³ The white line indicates the humeral head articular surface (HHS). The green line indicates the resulting transchondral direction (SD) according to the technique: parallel to the lateral border of the acromion in an internally rotated shoulder. The orange line indicates the modified position with 15° of lateral inclination. A theoretical 8 × 25-mm interference screw is demarcated (orange box).

caudal (Fig. 1, A). We previously set the humerus, with the forearm attached, in approximately 30° of internal rotation. Then, we placed the pins immediately adjacent to each other in the horizontal plane at the same distance (15 mm) from the upper portion of the groove because, otherwise, there would be a path conflict between them. All pins were parallel to the lateral border of the acromion.³ Caudal angulations were used intentionally to be closer to the axillary nerve. A posterior dissection was carried out to identify the axillary nerve and the exit of the Beath pin. Then, we measured the closer distance between the exit of the pin and the axillary nerve with a digital caliper (model E5001002; Veto, Santiago, Chile). Dissection was performed with special care taken not to alter the anatomic position of the nerve (Fig. 1, B). In the cases in which the pin exit was transchondral, the closer distance between the pin exit and the cartilage border was also measured.

In the second group, the 2.0-mm pins were set at the same position perpendicular to the groove but with 2 directions: parallel to the lateral border of the acromion, as in the first group,³ and at

15° of lateral inclination to the first pin. In this case, we set the second pin superior and immediately adjacent to the first one to prevent trajectory conflict, as explained previously. Figure 2 shows the theoretical result of the lateral inclination regarding the standard direction. Then, through a posterior dissection, the posterior exit of the pins in the humeral head was analyzed. In this group, the registered outcome was the presence or absence of chondral injury in both pin directions.

Statistical analysis was performed using STATA software (version 15; StataCorp, College Station, TX, USA). As this was an observational study, for the first group, we performed the analysis according to parametric variables, determining the mean, standard deviation, and 95% confidence interval. In the case of the second group, for nonparametric variables, we used the Fisher exact test because of the small number of specimens.

Results

Table 1 shows the first group's results. No pin injured the axillary nerve regardless of the angulation. As shown by the data, all pins passed through the posterior humerus away from the nerve. The closer pins to the axillary nerve were, as expected, in the 20° caudal inclination subgroup (mean, 18.8 mm), whereas the 0° subgroup was found to have the safer position (mean, 38.8 mm). All pins passed through the humeral head cartilage (Fig. 1, B); the 20° subgroup pins were the nearest to the cartilage border (mean, 6.1 mm).

Regarding the second group, in the subgroup with 15° of lateral inclination, no pins exited through the articular cartilage. Tilting the pin 15° laterally prevented chondral damage ($P = .008$).

Discussion

BT is an accepted method to treat biceps pathology with satisfactory results.^{2,5,6,10,17,19} There are many locations for BT and different possible complications during the procedure, including implant failure, proximal humeral fracture, and neurologic and vascular injuries.¹⁸

Published studies have warned about the risk of axillary nerve injury when performing bicortical drilling during BT,^{1,4,8,15,16} but most of them used a subpectoral position. To our concern, only 2 studies included suprapectoral BT, showing opposite results.^{8,16} In a cadaveric study, Sethi et al¹⁶ analyzed the axillary nerve risk during BT. They compared both suprapectoral and subpectoral BT with drilling through the posterior cortex for a cortical button technique, showing a high risk of nerve injury in the suprapectoral position. However, the site used by them was immediately superior to the upper edge of the pectoralis major, a far lower position than our selected location.³ Lancaster et al⁸ reported different results. In cadaveric specimens, they marked the axillary nerve with

Table I Measurement results

Pin position	Pin to axillary nerve, mm		Pin to cartilage border, mm	
	Mean \pm SD (range)	95% CI	Mean \pm SD (range)	95% CI
Perpendicular	38.8 \pm 8.7 (24.4-45.9)	28-49.6	16.7 \pm 3.9 (12.1-22)	11.9-21.5
10° caudal	28.9 \pm 7.8 (18.1-38.5)	19.2-38.6	9.8 \pm 3.7 (6.4-16)	5.2-14.4
20° caudal	18.8 \pm 10.7 (5.1-31.7)	5.5-32	6.1 \pm 4.8 (0-12.2)	0.1-12

SD, standard deviation; CI, confidence interval.

a metallic filament and then placed drill bits in a different position for a simulated BT. Computed tomography scans of the specimens showed the riskier position near the upper edge of the pectoralis major (10.7 mm) and the safer position near the upper edge of the bicipital groove (36.2 mm). These results are similar to our findings. We decided to test different inclinations intentionally, simulating possible mistakes during the arthroscopic procedure.

To our knowledge, articular cartilage damage during BT was not described before. As we found in the first group, by use of the described direction,³ all pins injured the humeral cartilage, regardless of the different vertical inclinations (Fig. 1, B). The perpendicular position had the longer pin-to-cartilage border width. So, in the second group, we performed drilling at 15° of lateral inclination in the same vertical position; in this group, no pin injured the cartilage. In the case of the selected BT technique,³ the chondral injury produced by the pin may be trivial, considering that the pin is just used for traction and then removed. Nevertheless, in the case of other fixation methods such as cortical buttons, this scenario could be dangerous for the risk of leaving the implant in an intra-articular position, if not on the cartilage itself. In addition, studies analyzing cortical buttons have warned about the dimensions of the implant in their results.^{1,4,15} This risk seems to be greater if we consider that variable. It is important to consider that a slightly lateralized inclination of the pin could prevent chondral injury.

There are some limitations of this study. First, the specimen number was small. We decided to divide the cadavers into 2 groups to prevent errors produced by repetitive drilling through the bone. Second, we decided to try, in the second group, only the lateral angulation regarding the perpendicular position, without attempts at caudal inclination. We consider that trying lateral angulation in each vertical scenario would not be necessary. As shown in Table I, the perpendicular position was the most medial exit through the cartilage. The intention was to define whether lateral inclination could prevent chondral injury; thus, no difference seems to be relevant, considering that the more caudal the inclination, the closer the needle was to the cartilage border, and therefore less angulation should be required.

Finally, this study analyzed suprapectoral BT using an interference screw by a bicortical drilling technique. Nevertheless, other techniques require the violation of the posterior humeral cortex as well (eg, cortical buttons). We believe our findings suppose a clinical interest beyond the current technique used by our institution.

Conclusion

Suprapectoral BT performed 15 mm distal to the upper edge of the bicipital groove for interference screw fixation using an anterior-to-posterior passage of a pin traction guide through the proximal humerus is a safe procedure for the axillary nerve. This technique implies a potential humeral chondral injury, which could be prevented with 15° of lateral inclination of the pin guide.

Disclaimer

The authors, their immediate families, and any research foundations with which they are affiliated have not received any financial payments or other benefits from any commercial entity related to the subject of this article.

References

1. Arora AS, Singh A, Koonce RC. Biomechanical evaluation of a unicortical button versus interference screw for subpectoral biceps tenodesis. *Arthroscopy* 2013;29:638-44. <https://doi.org/10.1016/j.arthro.2012.11.018>
2. Boileau P, Baqué F, Valerio L, Ahrens P, Chuinard C, Trojani C. Isolated arthroscopic biceps tenotomy or tenodesis improves symptoms in patients with massive irreparable rotator cuff tears. *J Bone Joint Surg Am* 2007;89:747-57. <https://doi.org/10.2106/JBJS.E.01097>
3. Boileau P, Krishnan SG, Coste J-S, Walch G. Arthroscopic biceps tenodesis: a new technique using bioabsorbable interference screw fixation. *Arthroscopy* 2002;18:1002-12. <https://doi.org/10.1053/jars.2002.36488>
4. Ding DY, Gupta A, Snir N, Wolfson T, Meislin RJ. Nerve proximity during bicortical drilling for subpectoral biceps tenodesis: a cadaveric study. *Arthroscopy* 2014;30:942-6. <https://doi.org/10.1016/j.arthro.2014.03.026>

5. Ek ET, Shi LL, Tompson JD, Freehill MT, Warner JJP. Surgical treatment of isolated type II superior labrum anterior-posterior (SLAP) lesions: repair versus biceps tenodesis. *J Shoulder Elbow Surg* 2014; 23:1059-65. <https://doi.org/10.1016/j.jse.2013.09.030>
6. Godenèche A, Kempf J-F, Nové-Josserand L, Michelet A, Saffarini M, Hannink G, et al. Tenodesis renders better results than tenotomy in repairs of isolated supraspinatus tears with pathologic biceps. *J Shoulder Elbow Surg* 2018;27:1939-45. <https://doi.org/10.1016/j.jse.2018.03.030>
7. Hitchcock HH, Bechtol CO. Painful shoulder; observations on the role of the tendon of the long head of the biceps brachii in its causation. *J Bone Joint Surg Am* 1948;30A:263-73.
8. Lancaster S, Smith G, Ogunleye O, Packham I. Proximity of the axillary nerve during bicortical drilling for biceps tenodesis. *Knee Surg Sports Traumatol Arthrosc* 2016;24:1925-30. <https://doi.org/10.1007/s00167-014-3214-z>
9. Mazzocca AD, Bicos J, Santangelo S, Romeo AA, Arciero RA. The biomechanical evaluation of four fixation techniques for proximal biceps tenodesis. *Arthroscopy* 2005;21:1296-306. <https://doi.org/10.1016/j.arthro.2005.08.008>
10. McCormick F, Nwachukwu BU, Solomon D, Dewing C, Golijanin P, Gross DJ, et al. The efficacy of biceps tenodesis in the treatment of failed superior labral anterior posterior repairs. *Am J Sports Med* 2014;42:820-5. <https://doi.org/10.1177/0363546513520122>
11. Neviaser AS, Patterson DC, Cagle PJ, Parsons BO, Flatow EL. Anatomic landmarks for arthroscopic suprapectoral biceps tenodesis: a cadaveric study. *J Shoulder Elbow Surg* 2018;27:1172-7. <https://doi.org/10.1016/j.jse.2018.01.007>
12. Nho SJ, Reiff SN, Verma NN, Slabaugh MA, Mazzocca AD, Romeo AA. Complications associated with subpectoral biceps tenodesis: low rates of incidence following surgery. *J Shoulder Elbow Surg* 2010;19:764-8. <https://doi.org/10.1016/j.jse.2010.01.024>
13. Rao AJ, Bernardoni E, Verma N, Trenhaile S. An all-arthroscopic, length-tensioned suprapectoral biceps tenodesis technique. *Arthrosc Tech* 2017;6:e1599-605. <https://doi.org/10.1016/j.eats.2017.06.016>
14. Rhee PC, Spinner RJ, Bishop AT, Shin AY. Iatrogenic brachial plexus injuries associated with open subpectoral biceps tenodesis: a report of 4 cases. *Am J Sports Med* 2013;41:2048-53. <https://doi.org/10.1177/0363546513495646>
15. Saithna A, Longo A, Jordan RW, Leiter J, MacDonald P, Old J. A cadaveric assessment of the risk of nerve injury during open subpectoral biceps tenodesis using a bicortical guidewire. *Knee Surg Sports Traumatol Arthrosc* 2017;25:2858-63. <https://doi.org/10.1007/s00167-015-3972-2>
16. Sethi PM, Vadasdi K, Greene RT, Vitale MA, Duong M, Miller SR. Safety of open suprapectoral and subpectoral biceps tenodesis: an anatomic assessment of risk for neurologic injury. *J Shoulder Elbow Surg* 2015;24:138-42. <https://doi.org/10.1016/j.jse.2014.06.038>
17. Szabo I, Boileau P, Walch G. The proximal biceps as a pain generator and results of tenotomy. *Sports Med Arthrosc* 2008;16:180-6. <https://doi.org/10.1097/JSA.0b013e3181824f1e>
18. Virk MS, Nicholson GP. Complications of proximal biceps tenotomy and tenodesis. *Clin Sports Med* 2016;35:181-8. <https://doi.org/10.1016/j.csm.2015.08.011>
19. Walch G, Edwards TB, Boulahia A, Nové-Josserand L, Neyton L, Szabo I. Arthroscopic tenotomy of the long head of the biceps in the treatment of rotator cuff tears: clinical and radiographic results of 307 cases. *J Shoulder Elbow Surg* 2005;14:238-46. <https://doi.org/10.1016/j.jse.2004.07.008>